



International  
Labour  
Organization

# ▶ Guidelines for the use of the ILO International Classification of Radiographs of Pneumoconioses

Revised edition 2022

Occupational  
Safety and Health  
Series

22

▶ **Guidelines for the use  
of the ILO International  
Classification of Radiographs  
of Pneumoconioses**

Revised edition 2022

**Occupational Safety and Health Series  
No. 22**

Copyright © International Labour Organization 2022  
First published 2022

Publications of the International Labour Organization (ILO) enjoy copyright under Protocol 2 of the Universal Copyright Convention. Nevertheless, short excerpts from them may be reproduced without authorization, on condition that the source is indicated. For rights of reproduction or translation, application should be made to ILO Publishing (Rights and Licensing), International Labour Office, CH-1211 Geneva 22, Switzerland, or by email: [rights@ilo.org](mailto:rights@ilo.org). The ILO welcomes such applications.

Libraries, institutions and other users registered with a reproduction rights organization may make copies in accordance with the licences issued to them for this purpose. Visit [www.ifrro.org](http://www.ifrro.org) to find the reproduction rights organization in your country.

---

*Guidelines for the use of the ILO International Classification of Radiographs of Pneumoconioses – Revised edition 2022.*  
International Labour Organization– Geneva: ILO, 2022.

ISBN 97-89-2-2037677-5 (print)  
ISBN 978-92-2-037676-8 (web PDF)

---

The designations employed in ILO publications, which are in conformity with United Nations practice, and the presentation of material therein do not imply the expression of any opinion whatsoever on the part of the ILO concerning the legal status of any country, area or territory or of its authorities, or concerning the delimitation of its frontiers.

The responsibility for opinions expressed in signed articles, studies and other contributions rests solely with their authors, and publication does not constitute an endorsement by the ILO of the opinions expressed in them.

Reference to names of firms and commercial products and processes does not imply their endorsement by the ILO, and any failure to mention a particular firm, commercial product or process is not a sign of disapproval.

Information on ILO publications and digital products can be found at: [www.ilo.org/publns](http://www.ilo.org/publns).

Printed in Switzerland

Produced by the Publications Production Unit (PRODOC) of the ILO.  
Graphic and typographic design, layout and composition,  
printing, electronic publishing and distribution.  
The ILO endeavours to use paper sourced from forests managed  
in an environmentally sustainable and socially responsible manner.

Code: JMB-REP

## ► Foreword to the 2022 revised edition

---

This 2022 revised edition of the *Guidelines for the use of the ILO International Classification of Radiographs of Pneumoconioses* transitions the ILO Classification to using a new set of modern, digitally acquired radiographic standard images.

Since 1950, the International Labour Organization (ILO) has promoted discussion and published a series of guidelines on how to classify chest radiographs of persons with pneumoconioses. The goals have been to standardize and improve classification methods for individual patients and workers, and to facilitate international comparisons of research reports, epidemiological investigations, and data on pneumoconioses. This revised edition of the ILO International Classification of Radiographs of Pneumoconioses is a further effort towards these objectives. Based on the principles that governed the development of earlier editions of the ILO Classification (those of 1950, 1958, 1968, 1971, 1980, 2000 and 2011), it refers to radiographic appearance of pneumoconiosis.

This revision of the *Guidelines* incorporates the selection of an entirely new set of digitally acquired standard images. This new set replaces the previous set of digitized analog standard images used in 2011-D edition.

This set of new digitally acquired standard images is the result of the collaboration between the ILO and the Respiratory Health Division of the United States National Institute for Occupational Safety and Health (NIOSH). Beginning in 2012, candidate images from dust-exposed populations worldwide were solicited, collected, reviewed, and classified by NIOSH and an international panel of expert readers. The ILO convened a three-day technical meeting of 18 expert readers in September 2018 in the premises of the ILO International Training Centre in Turin, Italy. In the months prior to the meeting, all members of the expert panel independently classified over 100 candidate images. During the meeting, participants peer-reviewed all the best performing candidate images and selected those that would replace the 2011 digital set of 22 standard images. Accordingly, some parts of the *Guidelines* were identified as requiring revision, and, at the same time, the importance of continuity in the ILO Classification was emphasized. With this in mind, the new set of digitally acquired standard images was selected to closely match the performance of the prior 2011 digitized radiographs.

The 2022 revised edition of the *Guidelines for the use of the ILO International Classification of Radiographs of Pneumoconioses* is accompanied by one set of digitally acquired radiographic images. This set consists of 23 radiographic images. Twenty-two of them are new digitally acquired full-size chest radiographic images. This set does not contain new digitally acquired radiographs illustrating u/u-sized irregular opacities as no appropriate images could be found, even after an extensive search. Thus, it was decided to retain the 2011 digitized radiograph which has three quadrants that reproduce the sections of the composite radiograph that was used in 1980 to depict increasing profusion of u/u-sized irregular opacities; the fourth quadrant illustrates subcategory 0/0.

Continuing use of the ILO International Classification of Radiographs of Pneumoconioses will contribute further to the protection of the health of workers occupationally exposed to dust.

## ► Acknowledgments

---

The 2022 revised edition of the digital ILO International Classification of Radiographs of Pneumoconioses is the result of the collaboration between the ILO and NIOSH. Dr Begoña Casanueva Urcullu (ILO) and Dr Cara Halldin (NIOSH) supervised and coordinated the work.

The development of this revised edition of the ILO Classification of digital images has been made possible by virtue of intensive and sustained activity on the part of many individuals and organizations. The ILO is grateful to the experts from nine countries who participated in a three-day technical meeting in Turin, Italy. (See Appendix F). Their enthusiastic and intensive work during the meeting and in the months preceding and following those three days enabled the 2022 revised edition of the ILO Classification of digital images, this is, the 23 standard digital images and the accompanying *Guidelines*. Others, too numerous to list, provided valuable images, comments, and suggestions in writing and by contributing to discussions at various scientific meetings.


The ILO wishes to express its gratitude to Dr Robert Cohen, Dr Cara Halldin, Dr Kurt G. Hering, Dr Yutaka Hosoda, Dr Michael Jacobsen, Dr Yukinori Kusaka, Mr Otha W. Linton, Dr John E. Parker, Dr Edward Petsonk, Dr Anthony V. Proto, Dr David Rees, Dr Hisao Shida, Dr Robert Tallaksen, Dr Gregory R. Wagner, Dr Jerome F. Wiot and Dr Anders Zitting for their assistance in the preparation of the appendices.

Thanks are due as well to Mr Félix Martin Daza (ILO) for the organization of the technical meeting in September 2018 in the premises of the ILO International Training Centre in Turin, Italy, and to Ms Paola Costantini for the administrative support to the meeting.

## ▶ Contents

---

▶ Foreword to the 2022 revised edition	iii
▶ Acknowledgments	iv
<hr/>	
▶ 1. Introduction	1
<hr/>	
▶ 2. General instructions	2
<hr/>	
▶ 3. Specific instructions for the use of the ILO Classification	3
3.1 Technical quality	3
3.2 Parenchymal abnormalities	3
3.3 Pleural abnormalities	6
3.4 Symbols	9
3.5 Comments	11
<hr/>	
▶ 4. Specific instructions for the use of the Abbreviated ILO Classification	12
<hr/>	
▶ 5. Using the ILO Classification	13
<hr/>	
▶ 6. Using the ILO Classification for digital chest radiographs	14
<hr/>	
▶ 7. Appendices	17
Appendix A Notes on technical quality for chest radiographs of dust- exposed workers	18
Appendix B Reading sheets	20
Appendix C Description of the ILO 2022 standard digital images	23
Appendix D Diagrams	28
Appendix E Summary of the details of the ILO standard digital images	33
Appendix F Participants in the ILO convened meeting leading to the 2022 revised edition of the digital ILO International Classification of Radiographs of Pneumoconioses	36



## ► 1. Introduction

---

### Scope of the Classification

The Classification provides a means for describing and recording systematically the radiographic abnormalities in the chest provoked by the inhalation of dusts. It is used to describe radiographic abnormalities that occur in any type of pneumoconiosis and is designed for classifying only the appearances seen on postero-anterior chest radiographs. Other views and imaging techniques may be required for clinical assessment of individuals, but the ILO International Classification has not been designed to code such findings.

### Object of the Classification

The object of the Classification is to codify the radiographic abnormalities of the pneumoconioses in a simple, reproducible manner. The Classification neither defines pathological entities nor takes into account working capacity. It does not imply legal definitions of pneumoconioses for compensation purposes and does not set or imply a level at which compensation is payable.

### Uses of the Classification

The Classification is used internationally for epidemiological research, for screening and surveillance of those in dusty occupations, and for clinical purposes. Use of the scheme may lead to better international comparability of data concerning the pneumoconioses.

### Standard radiographs and written definitions

The Classification consists of a set of standard radiographs and this text, with the accompanying footnotes. These footnotes are intended to reduce ambiguity and are based on experience with earlier editions of the ILO Classification. In some parts of the scheme, the standard radiographs are considered calibration radiographs, and take precedence over the written definitions. In other parts, the standard radiographs are only considered examples. The text makes it clear when this is so. See Chapter 3 and Appendix C.



## ▶ 2. General instructions

---

No radiographic features are pathognomonic of dust exposure. Some radiographic features that are unrelated to inhaled dust may mimic those caused by dust. Readers may differ about the differential diagnosis of potential causes of such appearances.

In epidemiological studies, therefore, the study protocol will usually require that all appearances described in these *Guidelines* and seen on the standard radiographs are to be classified. Symbols must always be used and appropriate comments must be reported.<sup>1</sup>

When the Classification is used for some clinical purposes, the protocol may require that medical readers classify only those appearances which the reader believes or suspects to be pneumoconiotic in origin. In this case, symbols must always be used and appropriate comments detailing appearances described in these *Guidelines* and the rationale for not classifying them must be reported.

---

<sup>1</sup> See sections 3.4 and 3.5.

## ▶ 3. Specific instructions for the use of the ILO Classification

### 3.1 Technical quality<sup>2,3</sup>

Four grades of technical quality are used:

1. Good.
2. Acceptable, with no technical defect likely to impair classification of the radiograph for pneumoconiosis.
3. Acceptable, with some technical defects but still adequate for classification purposes. Note: Technical defects may potentially impair the classification.
4. Unacceptable for classification purposes.

If the technical quality of the radiograph is not recorded as grade 1 (good), then a comment describing the technical defect(s) should be made at that time, before proceeding with the classification.

### 3.2 Parenchymal abnormalities

Parenchymal abnormalities include both small opacities and large opacities (see **Figure 1**).

#### Small opacities

Small opacities are described by profusion, affected zones of the lung, shape (rounded or irregular) and size. The order of identifying and recording the presence or absence of these findings while classifying a radiograph is left to the reader's preference.

#### Profusion

The profusion of small opacities refers to the concentration of small opacities in affected zones of the lung. The category of profusion is based on comparisons with the calibration standard radiographs. For profusion the written descriptions are a guide, but the standard radiographs take precedence.

Increasing profusion of small opacities <span style="float: right;">→</span>												
Categories	0			1			2			3		
Subcategories	0/-	0/0	0/1	1/0	1/1	1/2	2/1	2/2	2/3	3/2	3/3	3/+

<sup>2</sup> Appendix A emphasizes the importance of good radiographic quality for the interpretation of chest radiographs. It is essential to produce radiographs that clearly show both parenchymal and pleural characteristics. For clinical purposes, special views or techniques may also be required. When it is not possible to replace a grade 3 radiograph by a better one, more details about technical defects should be recorded.

<sup>3</sup> The standard radiographs are not to be considered in determining technical quality of the subject radiographs. The standard radiographs were chosen to demonstrate the radiographic features of the pneumoconioses, rather than to demonstrate technical quality.

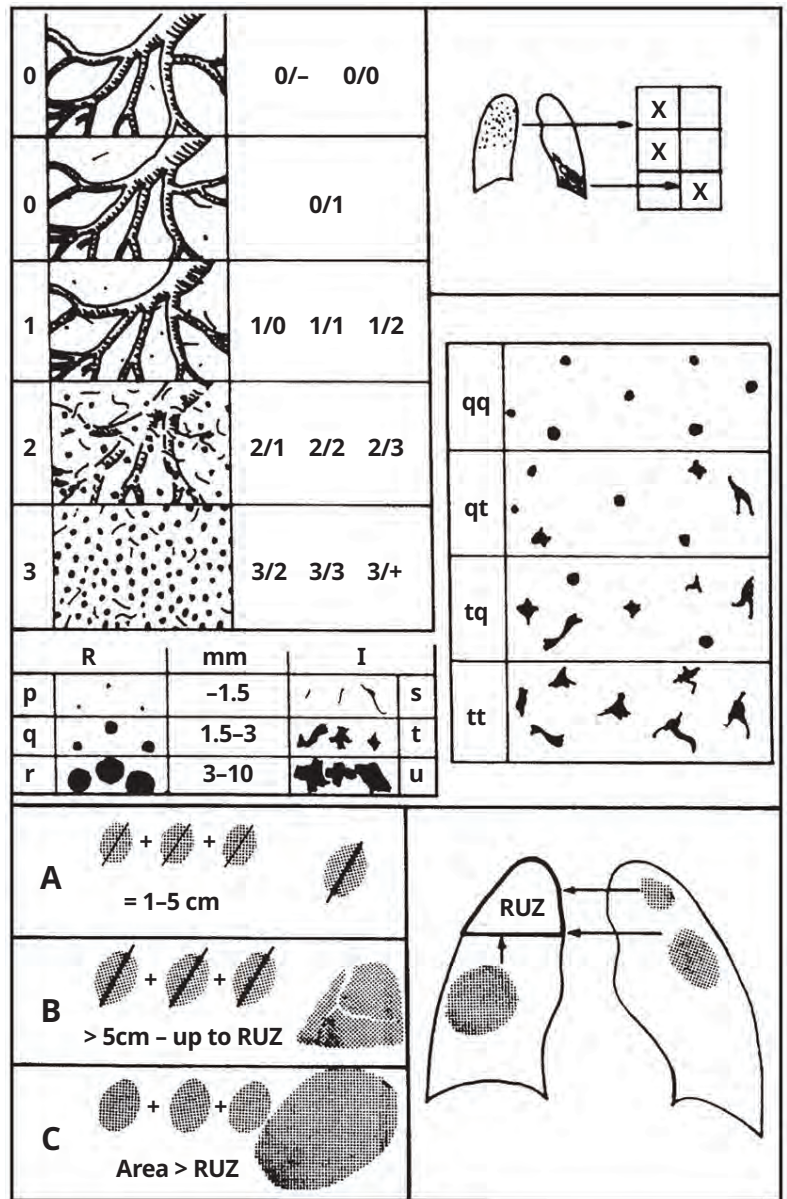
Four categories are defined by the standard radiographs. Profusion is classified into one of 12 ordered subcategories, which are represented symbolically as follows.<sup>4</sup> Category **0** refers to the absence of small opacities or the presence of small opacities that are less profuse than category **1**.

Classification of a radiograph using the 12-subcategory scale is performed as follows. The appropriate category is chosen by comparing a subject radiograph with standard calibration radiographs that define the levels of profusion characteristic of the centrally placed subcategories (**0/0**, **1/1**, **2/2**, **3/3**) within these categories. The category is recorded by writing the corresponding symbol followed by an oblique stroke, i.e. **0/**, **1/**, **2/**, **3/**. If no alternative category was seriously considered, the radiograph is classified into the central subcategory, i.e. **0/0**, **1/1**, **2/2**, **3/3**. For example, a radiograph that shows profusion which is considered to be similar to that shown on a subcategory **2/2** standard radiograph, i.e. neither category **1** nor **3** was seriously considered as an alternative, would be classified as **2/2**.

However, subcategory **2/1** refers to a radiograph with profusion of small opacities judged to be similar in appearance to that depicted on a subcategory **2/2** standard radiograph, but category **1** was seriously considered as an alternative before deciding to classify it as category **2**.

The standard radiographs provide two examples of appearances classifiable as subcategory **0/0**. Subcategory **0/0** refers to radiographs where there are no small opacities, or if a few are thought to be present, they are not sufficiently definite or numerous for category **1** to have been seriously considered as an alternative. Subcategory **0/1** is used for radiographs classified as category **0** after having seriously considered category **1** as an alternative. Subcategory **1/0** is used for radiographs classified as category **1** after having seriously considered category **0** as an alternative. If the absence of small opacities is particularly obvious, then the radiograph is classified as subcategory **0/-**.

A radiograph showing profusion greater than that depicted on a subcategory **3/3** standard radiograph is classified as subcategory **3/+**.



► Figure 1.5 Illustrations describing range of small opacity profusion, affected zones, examples of small opacity shape and size, and categories of large opacities.

4 The 12 subcategories refer only to the profusion of small opacities. Profusion, including references to subcategories 0/- or 0/0 when appropriate, must always be recorded, irrespective of any other abnormalities that may be present. Conversely, when other abnormalities are seen, their presence must also be recorded, irrespective of whether any small opacities are present. The subcategories are arbitrary divisions of an underlying continuum of increasing profusion of small opacities. Those divisions are defined by the standard radiographs, together with the instructions for their use. The validity of the classification procedure to represent this continuum has been demonstrated in studies of relationships between results obtained by using the ILO Classification and (a) indices of cumulative exposures to various dusts; (b) the dust content of coalminers lungs post mortem; (c) mortality of asbestosis workers and coalminers; and (d) pathological appearances of coalminers lungs post mortem.

5 Illustrations are intended to serve as pictorial reminders and are not a substitute for the standard radiographs or written text.

### Affected zones

The zones in which the opacities are seen are recorded. Each lung field is divided into three zones (upper, middle, lower) by horizontal lines drawn at approximately one-third and two-thirds of the vertical distance between the lung apices and the domes of the diaphragm.

The overall profusion of small opacities is determined by considering the profusion as a whole averaged over the affected zones of the lungs. When there is a marked (three subcategories or more) difference in profusion in different zones of the lungs, then the zone or zones showing the marked lesser degree of profusion is/are ignored for the purpose of classifying the overall profusion.<sup>6</sup>

### Shape and size

For shape and size, the written definitions are a guide, and the standard radiographs take precedence. The shape and size of small opacities are recorded. Two kinds of shape are recognized: rounded and irregular. In each case, three sizes are differentiated.

For small rounded opacities, the three size ranges are denoted by the letters **p**, **q** and **r**, and are defined by the appearances of the small opacities on the corresponding standard radiographs. These illustrate:

**p** = opacities with diameters up to about 1.5 mm;

**q** = opacities with diameters exceeding about 1.5 mm and up to about 3 mm;

**r** = opacities with diameters exceeding about 3 mm and up to about 10 mm.

The three size ranges of small irregular opacities are denoted by the letters **s**, **t** and **u**, and are defined by the appearances of the small opacities on the corresponding standard radiographs. These illustrate:

**s** = opacities with widths up to about 1.5 mm;

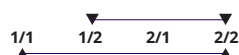
**t** = opacities with widths exceeding about 1.5 mm and up to about 3 mm;

**u** = opacities with widths exceeding about 3 mm and up to about 10 mm.

<sup>6</sup> A "marked (three subcategories or more) difference" in profusion in different zones of the lung is present when there are two or more subcategories of profusion between the zone (or zones) of the lowest profusion and the zone (or zones) of the highest profusion. For example, if a subject radiograph displays zones with profusion levels **1/1**, **1/2**, **2/1** and **2/2**, the overall profusion is determined by ignoring the zone with profusion level **1/1**, since two or more subcategories (**1/2**, **2/1**) are between that zone and the zone of the highest profusion (**2/2**). The overall profusion, therefore, is determined by considering only the affected zones showing profusion levels **1/2**, **2/1** and **2/2**, since there is only one subcategory of profusion (**2/1**) between profusion levels **1/2** and **2/2**.

#### Example 1

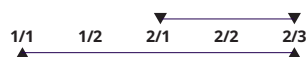
Only one intervening subcategory between the zones of lowest (**1/2**) and highest (**2/2**) profusion; use all three to determine overall profusion.



There are two intervening subcategories between the zones of lowest (**1/1**) and highest (**2/2**) profusion; ignore **1/1** to determine overall profusion.

#### Example 2

Only one intervening subcategory between the zones of lowest (**2/1**) and highest (**2/3**) profusion; use all three to determine overall profusion.



There are three intervening subcategories between the zones of lowest (**1/1**) and highest (**2/3**) profusion; ignore **1/1** and **1/2**; use **2/1**, **2/2**, **2/3** to determine overall profusion since there is only one subcategory between **2/1** and **2/3**.

All zones in which opacities are seen are considered, irrespective of whether some are later ignored in determining overall profusion.

Two letters must be used to record shape and size. Thus, if the reader considers that all, or virtually all, opacities seen are of one shape and size, then this is noted by recording the letter twice, separated by an oblique stroke (for example **q/q**). If, however, significant numbers of another shape or size are seen, then this is recorded by writing a different letter after the oblique stroke (for example **q/t**); **q/t** would mean that the predominant small opacities are rounded and of size **q**, but that there are significant numbers of small irregular opacities present of size **t**. In this way, combinations of small opacities of two shapes or sizes may be recorded.<sup>7</sup> When small opacities of different shapes and/or size are seen, the letter for the predominant shape and size (primary) is recorded before the oblique stroke, while the letter for the less frequently occurring shape and size (secondary) is recorded after the oblique stroke.

## Large opacities

A large opacity is defined as an opacity having the longest dimension exceeding 10 mm. Categories of large opacities are defined below. These definitions take precedence over the large opacities illustrated on the example standard radiographs.

### Category A

One large opacity having the longest dimension up to about 50 mm, or several large opacities with the sum of their longest dimensions not exceeding about 50 mm.

### Category B

One large opacity having the longest dimension exceeding 50 mm but not exceeding the equivalent area of the right upper zone, or several large opacities with the sum of their longest dimensions exceeding 50 mm but not exceeding the equivalent area of the right upper zone.

### Category C

One large opacity which exceeds the equivalent area of the right upper zone, or several large opacities which, when combined, exceed the equivalent area of the right upper zone.

## 3.3 Pleural abnormalities

Pleural abnormalities are divided into pleural plaques (localized pleural thickening), costophrenic angle obliteration, and diffuse pleural thickening. The range of pleural abnormalities is depicted in **Figure 2**. Recording pleural abnormalities may utilize the Chest Radiograph Classification Form or the Reading Sheet for the Abbreviated ILO Classification, both found in Appendix B.

### Pleural plaques (localized pleural thickening)

Pleural plaques represent localized pleural thickening, generally of the parietal pleura. Pleural plaques may be seen on the diaphragm, on the chest wall (in-profile or face-on), and at other sites. At times, they are recognized only by their calcification. Pleural plaques are recorded as absent or present. If present on the chest wall, they are recorded as in-profile or face-on, and separately for the right and left sides. A minimum width of about 3 mm is required for an in-profile plaque to be recorded as present.<sup>8,9</sup>

Site, calcification and extent of pleural plaques are recorded separately for the right and for the left side of the chest. The written guidelines describing these features take precedence over the examples provided on the standard radiograph.

<sup>7</sup> See Appendix D for possible combinations.

<sup>8</sup> The measurement of width is made from the innermost margin of the rib to the innermost sharp margin of the plaque at the pleural-parenchymal boundary.

<sup>9</sup> If more detailed measurement of width is required for a particular study, three categories may be used:

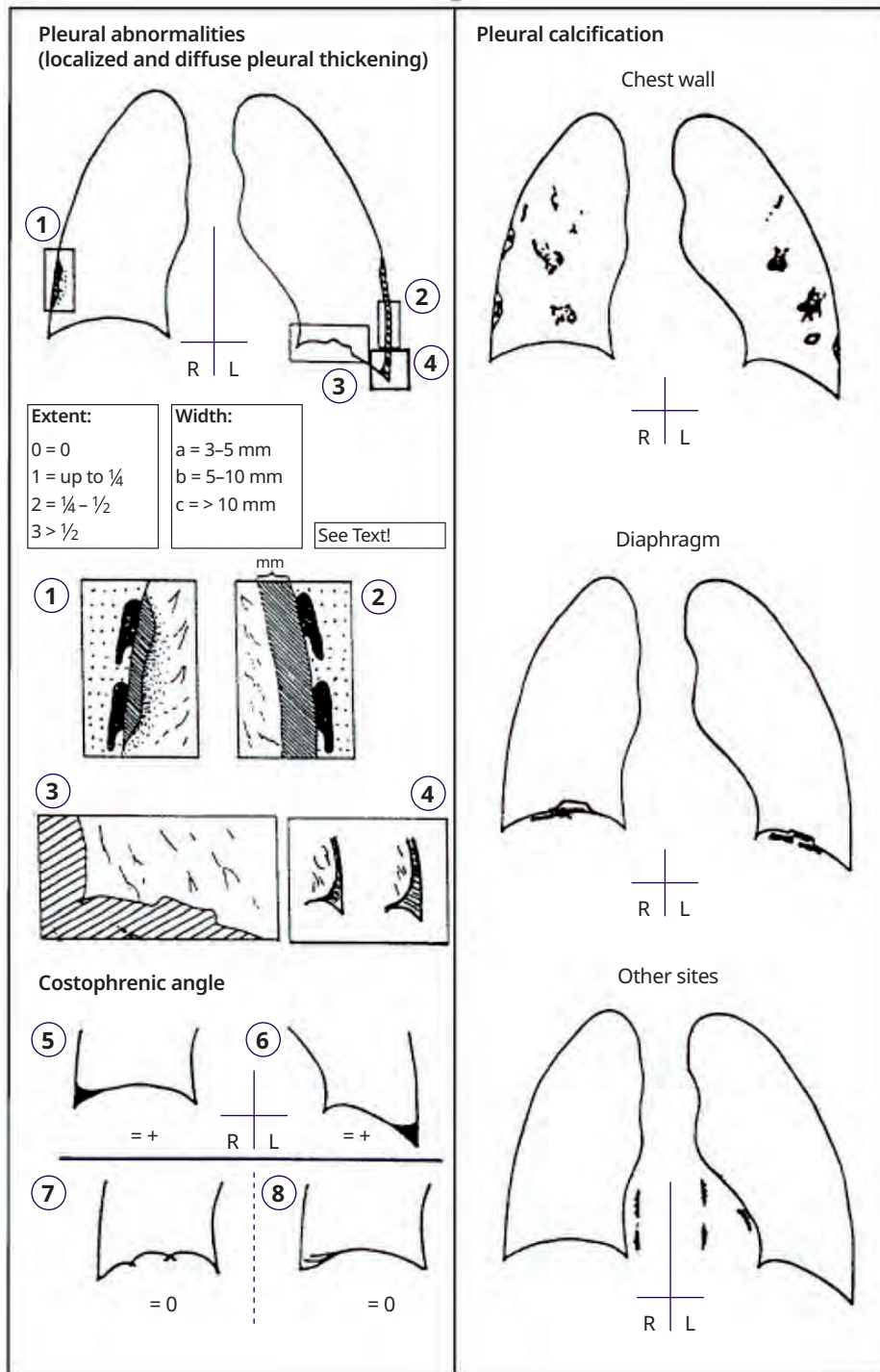
**a** = about 3 mm up to about 5 mm;

**b** = over about 5 mm up to about 10 mm;

**c** = over about 10 mm.

**Site**

The sites (locations) of pleural plaques include chest wall, diaphragm, and other sites. Other sites include the mediastinal pleura in the para-spinal or para-cardiac locations. The presence or absence of pleural plaques is recorded for all sites, and separately for the right and for the left sides.



► Figure 2.10 Illustrations depicting a range of pleural abnormalities.

10 See footnote 5.

## Calcification

Radiographic images of pleural plaques may include recognizable areas of calcification. The presence or absence of calcification is recorded for all plaques, and separately for the right and for the left sides. When calcification is seen, a plaque is also recorded as present at that site.

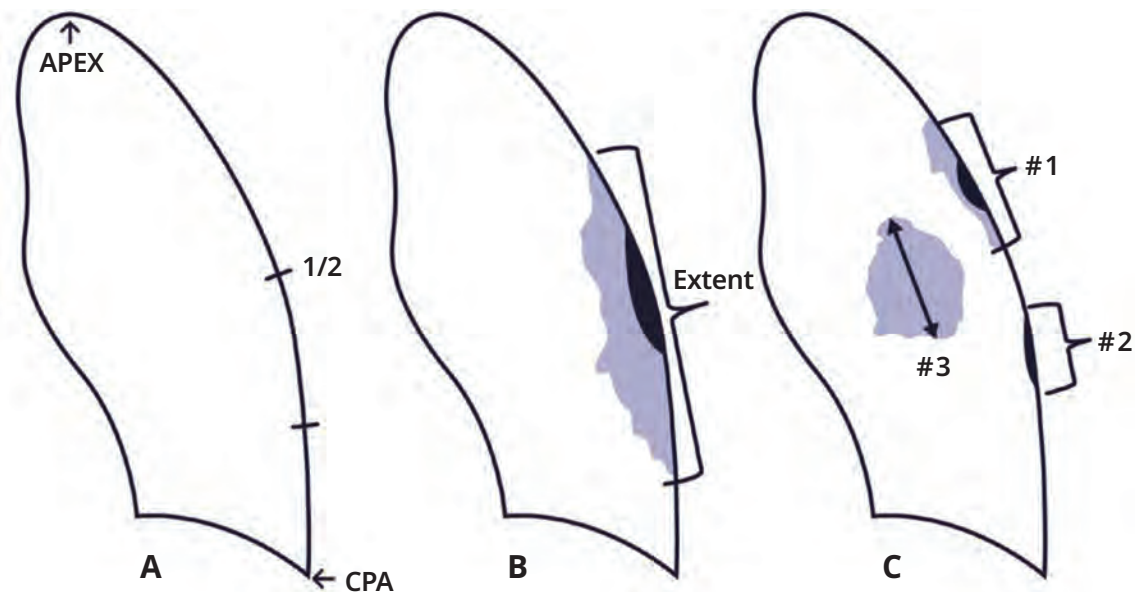
## Extent

Extent is not recorded for plaques on the diaphragm or at other sites. It is recorded only for plaques along the chest wall, and is combined for both in-profile and face-on varieties. Extent is defined in terms of the total length of involvement with respect to the projection of the lateral chest wall (from the apex to the costophrenic angle, or if the costophrenic angle is blunted, use your best estimate of the level) on the postero–anterior chest radiograph:

- 1 = up to one-quarter of the total length of the lateral chest wall from APEX to CPA;
- 2 = exceeding one-quarter and up to one-half of the lateral chest wall from APEX to CPA;
- 3 = exceeding one-half of the lateral chest wall from APEX to CPA.

Extent is measured along the chest wall from the highest point of the apex (labeled “APEX”) to the lowest point (nearest the costophrenic angle, labeled “CPA”) on the posterior-anterior chest radiograph (**Figure 3A**).

The projection is measured along the involved chest wall from the highest point of thickening (nearest the apex) to the lowest point (nearest the costophrenic angle) along the thorax wall, as shown in **Figure 3B**.



► **Figure 3.<sup>11</sup> Pleural plaques, face-on, mixed profile, and face-on extent.** Refer to the text descriptions of items A, B, and C for examples of how extent of pleural plaques is measured.

In **Figure 3B** an in-profile and face-on plaque is demonstrated and should be classified as extent 3 because it exceeds one half of the lateral chest wall.

In **Figure 3C** three separate plaques (1–3) which are in-profile and face-on are demonstrated. The sum of their lengths determines this to be extent 3.

## Costophrenic angle obliteration

Costophrenic angle obliteration is recorded as either present or absent, separately for the right and for the left side. The lower limit for recording costophrenic angle obliteration is defined by the standard calibration radiograph labeled **CP Angle**. If the pleural thickening extends up the lateral chest wall from the obliterated costophrenic angle, the thickening should be classified as diffuse pleural thickening. Costophrenic angle obliteration may occur without diffuse pleural thickening.

The left lower panel of **Figure 2 (parts 5–7)** provides pictorial examples of the costophrenic angles; the top lung silhouettes depict a right (**Figure 2 part 5**) and left lung (**Figure 2 part 6**) with presence of costophrenic angle blunting bilaterally, without pleural thickening nearby. The lower two lung silhouettes are pictorial examples, both of the right lung, demonstrating variants of the diaphragmatic surface which are not considered costophrenic angle obliteration. The left silhouette (**Figure 2 part 7**) is an example of diaphragmatic scalloping, a hump formation, or with a Morgagni or Bochdalek hernia. The striations across the angle in the right silhouette (**Figure 2 part 8**) are muscle insertions which can become visible upon a deep inspiration and often misinterpreted as adherence. This finding can also be seen in the hyperinflation of emphysema, in which case the other symbol for emphysema (**em**) must be specified (see section 3.4 for the use of other symbols).

## Diffuse pleural thickening

Diffuse pleural thickening historically has referred to thickening of the visceral pleura. The radiological distinction between parietal and visceral pleural thickening is not always possible on a postero–anterior radiograph. For the purpose of the ILO (2022) Classification, diffuse pleural thickening extending up the lateral chest wall is recorded only in the presence of, and in continuity with, an obliterated costophrenic angle. Diffuse pleural thickening is recorded as absent or present along the chest wall. If present, it is recorded as in-profile or face-on, and separately for the right and the left side. Its extent is recorded in the same manner as for pleural plaques. A minimum width of about 3 mm is required for in-profile diffuse pleural thickening to be recorded as present. If detailed measurement of its width is required for a particular study, see the comment provided in footnote 9. Diffuse pleural thickening, as defined above, has been associated with restrictive functional impairment, while localized pleural thickening or pleural plaques have generally been associated with limited functional impairment in population-based studies.

Calcification and extent of diffuse pleural thickening on the chest wall are recorded separately for the right and for the left side (see guidelines for pleural plaques). The pleura may often be seen to be thickened only at the apex of the lung in unexposed persons and is not generally recorded as part of diffuse pleural thickening of the chest wall.

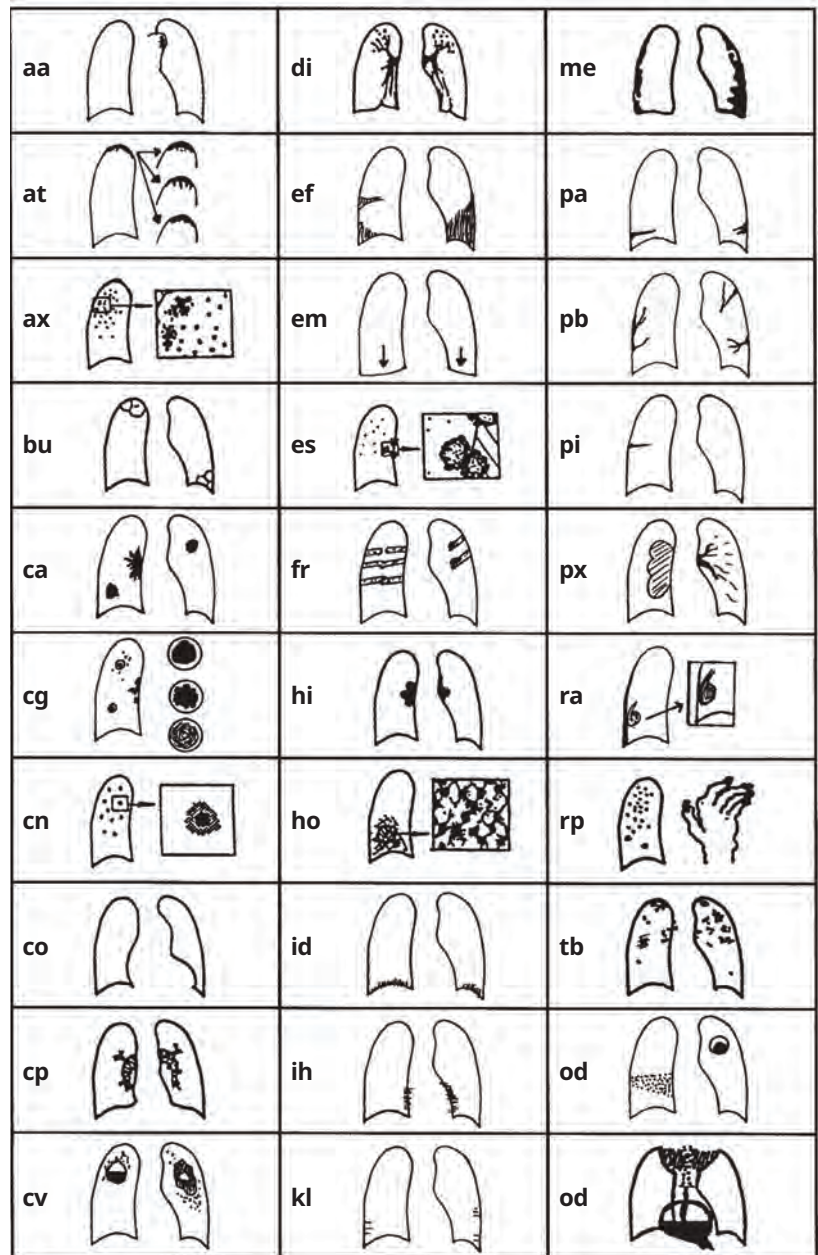
## 3.4 Symbols

Symbols to record radiographic features of importance are listed below and depicted in **Figure 4**. Their use is relevant because they describe additional features related to dust exposure and other etiologies. Use of these symbols is obligatory.<sup>12</sup> Some of the symbols imply interpretations or diagnoses, rather than just descriptions, of what is seen on the radiograph. A postero–anterior chest radiograph on its own may not be sufficient to justify definitive interpretation or diagnosis; therefore, each of the following definitions of symbols assumes an introductory qualifying word or phrase such as “changes indicative of”, or “findings suggestive of”, or “suspect”.

<sup>12</sup> Inclusion of this information in statistical analyses of results may help to explain otherwise inexplicable variation between readers in their classifications of the same radiographs. Reading forms may be modified to include check box lists of other common findings.



- aa** atherosclerotic aorta
- at** significant apical pleural thickening (see Appendix D)
- ax** coalescence of small opacities<sup>13</sup>
- bu** bulla(e)
- ca** cancer: thoracic malignancies excluding mesothelioma
- cg** calcified non-pneumoconiotic nodules (e.g. granuloma) or nodes
- cn** calcification in small pneumoconiotic opacities
- co** abnormality of cardiac size or shape
- cp** cor pulmonale
- cv** cavity
- di** marked distortion of an intra-thoracic structure
- ef** pleural effusion
- em** emphysema
- es** eggshell calcification of hilar or mediastinal lymph nodes
- fr** fractured rib(s) (acute or healed)
- hi** enlargement of non-calcified hilar or mediastinal lymph nodes
- ho** honeycomb lung
- id** ill-defined diaphragm border<sup>14</sup>
- ih** ill-defined heart border<sup>15</sup>
- kl** septal (Kerley) lines
- me** mesothelioma
- pa** plate atelectasis
- pb** parenchymal bands
- pi** pleural thickening of an inter-lobar fissure
- px** pneumothorax
- ra** rounded atelectasis
- rp** rheumatoid pneumoconiosis
- tb** tuberculosis<sup>16</sup>
- od** other disease or significant abnormality<sup>17</sup>



► **Figure 4.18** Diagrams representing the other symbols. These do not illustrate all the manifestations of the conditions defined by these symbols, for example **ca** (carcinoma), **cg** (calcified granuloma), **od** (other disease). The two drawings of appearances classifiable as **od** here represent lobar pneumonia and aspergilloma, goiter and hiatal hernia.

13 The symbol **ax** represents coalescence of small opacities with margins of the small opacities remaining visible, whereas a large opacity demonstrates discernible borders in whole or in part, associated with an underlying relatively homogeneous opaque appearance. The symbol **ax** (coalescence of small opacities) may be recorded either in the presence or in the absence of large opacities.

14 The symbol **id** (ill-defined diaphragm border) should be recorded only if more than one-third of one hemidiaphragm is affected.

15 The symbol **ih** (ill-defined heart border) should be recorded only if the length of the heart border affected, whether on the right or on the left side, is more than one-third of the length of the left heart border.

16 The symbol **tb** should be used for either suspect active or suspect inactive tuberculosis. The symbol **tb** should not be used for the calcified granuloma of tuberculosis or other granulomatous processes, e.g. histoplasmosis. Such appearances should be recorded as **cg**.

17 If the symbol **od** is used, then an explanatory comment must be made.

18 See footnote 5.

## 3.5 Comments

Comments are required if the symbol **od** (other disease) is recorded, and to identify any part of the reading of a chest radiograph which is believed by a reader to be probably or certainly not dust related. Comments should also be recorded to provide other relevant information.

## ► 4. Specific instructions for the use of the Abbreviated ILO Classification

---

The Abbreviated ILO Classification, described below, is a simplified version of the ILO Classification and includes its major components.

### Technical quality

The recording of the technical quality of the radiograph is the same as for the ILO Classification (see section 3.1).

### Small opacities

Profusion is determined by comparison with standard radiographs and recorded as one of the categories: **0**, **1**, **2**, or **3** (see section 3.2). Shape and size are determined by comparison with standard calibration radiographs. The predominant shape and size are recorded using only one of the following letters: **p**, **q**, **r**, **s**, **t**, or **u** (see section 3.2).

### Large opacities

Large opacities are recorded as size **A**, **B**, or **C** in the same way as for the ILO Classification (see section 3.2).

### Pleural abnormalities

All types of pleural thickening are recorded by the letters **PT**. All types of pleural calcifications are recorded by the letters **PC**.

### Symbols

Symbols are recorded as for the ILO Classification (see section 3.4).

### Comments

Comments are recorded as for the ILO Classification (see section 3.5).

## ► 5. Using the ILO Classification

---

Efficient use of the ILO Classification requires good viewing and recording conditions. The following recommendations are particularly important for epidemiological studies.

### Epidemiological reading protocols

When classifying radiographs for epidemiological purposes, it is essential that the reader does not consider any other information about the individuals being studied. Awareness of supplementary details specific to individuals can introduce bias into results. If the epidemiological objective is to make comparisons between two or more groups, then the radiographs from all groups should be mixed and presented to the reader in random order. Failure to observe these principles may invalidate conclusions from the study.

### Recording

Recording of results should be standardized and systematic. It is important to make provision for recording explicitly the presence or absence of all features to be evaluated for a particular study. Clerical help for recording results is valuable when classifying large numbers of radiographs. The clerical assistant should be asked to remind the reader of failure to report the presence or absence of any features to be analyzed in the study.

### Reading rates

The number of radiographs classifiable per unit of time can vary greatly. Factors influencing reading rates include the technical quality of the radiographs, the prevalence of abnormalities on the radiographs, the experience of the reader, the purpose of the reading exercise and the length of the reading session.

### Number of readers

It is recognized that there is considerable variation in multiple readings of some radiographs, not only from reader to reader (inter-observer variation), but also between readings by the same reader (intra-observer variation). It is recommended that, in epidemiological studies, at least two, but preferably more, readers each classify all radiographs independently.

When many radiographs are being read, intra-observer variation, i.e. variation in repeated readings by the same reader, should be assessed.

## ► 6. Using the ILO Classification for digital chest radiographs

---

### Purpose

The purpose of this chapter is to extend the applicability of the ILO International Classification of Radiographs of Pneumoconioses to digital radiographic images of the chest using the updated ILO 2022 digital images.

### Introduction

This chapter provides guidance on how to classify digital images of the chest in a way that maintains continuity and consistency with previous editions of the ILO Classification. Valid application of the ILO Classification to digital chest images requires users to adhere to all recommendations in this chapter, and to remain alert to future developments in digital chest imaging techniques.

### The ILO 2022 standard digital images

The 23 updated ILO 2022 digitally acquired images are available from the ILO website for download free of charge.

These ILO 2022 digital images define and illustrate the shapes, sizes and profusion of small opacities visible on digital images. The corresponding text in Chapter 3 provides supplementary information, and the appearances of the 16 calibration digital images (**1/1**, **2/2**, **3/3** for **p**, **q**, **r**, **s**, **t** and the one digitized quadrant image for **u/u**) take precedence for classification purposes. In addition, the film labeled **CP Angle** defines the lower limit of normal for costophrenic angle blunting. On the other hand, the example digital images of a normal chest radiograph, large opacities (**A**, **B**, and **C**), and of pleural abnormalities represent examples of those features. Their size, location and other characteristics are defined in Chapter 3, and for classification purposes that text takes precedence.

### Viewing principles

The high resolution radiology monitors used to view the chest images to be classified and the ILO digital images must be close enough for the observer to see opacities only 1 mm in diameter, that is, a distance of about 250 mm. It is also essential to view the entire chest image. The observer should be seated comfortably.

The viewing surfaces must be clean and the intensity of illumination should be uniform over all surfaces. The general illumination in the room should be low, without direct daylight. The room should be quiet, comfortable and free from distractions.

When viewing and classifying a subject's digital image (also known as "soft copy"<sup>19</sup>), the ILO 2022 digital images must be used. Subject and standard ILO 2022 digital images should be displayed on medical-grade flat-panel monitors designed for diagnostic radiology. The diagonal display should be at least 21" (54 cm) per image, with a ratio of maximum to minimum luminance at least 50; a maximum luminance of at

---

<sup>19</sup> *Soft copy* – A soft copy is a digital image displayed on a monitor. For classification purposes, digital images should be displayed on medical-grade flat-panel monitors designed for diagnostic radiology.

least 250 candelas per m<sup>2</sup>; pixel pitch no greater than 210 µm; and with resolution at least 2.5 line-pairs per mm.<sup>20</sup> The subject and ILO 2022 digital images should be displayed simultaneously, similarly sized, side-by-side.

### Examples of approaches not recommended for viewing digital images include:

- ▶ Displaying the images on a personal computer screen rather than on a medical-grade flat-panel monitor designed for diagnostic radiology.
- ▶ Comparing the subject digital image to ILO standard analog radiographs displayed on a view box.
- ▶ Viewing the subject digital image, or the ILO 2022 digital images, or both in formats reduced to less than two-thirds of their full size.
- ▶ Using digital images printed on film or paper for classification.

As with all radiographic viewing activities, procedures should be followed to ensure an appropriate environment, including restriction of ambient light sources and other distracting factors. (See Chapter 5 of these *Guidelines*.)

## Acquisition, display, and storage of digital chest images

Radiographic systems for collecting, displaying, and storing chest images for classification of pneumoconiosis should adhere to the most recent version of the Digital Imaging and Communications in Medicine (DICOM) standards or other comparable standards (for example, MEDICOM EN12052). The DICOM standards ([dicomstandard.org](http://dicomstandard.org)) are widely accepted and used internationally for radiographic imaging. They specify a common format for storage and transfer of digital images, and for brightness, contrast levels, and a consistent grey scale when presenting images on display monitors and printing digital images.

## Additional notes and recommendations<sup>21</sup>

### Imaging equipment

Hardware for production of digital chest images is manufactured and distributed by many commercial entities with varying approaches to image capture. A group of systems based on storage-phosphor technology is known as computed radiography (CR). A second group of systems, known as digital radiography (DR) relies on active matrix flat panels. CR is a mechanical system, using analog technology to take X-ray exposures with CR cassettes in place of traditional film cassettes. The CR system can then scan the image into a digital format. DR provides some additional benefits including enhanced overall image

<sup>20</sup> Definitions and further explanations of technical terms, as well as other information relevant to digital radiography, can be found in publications by professional associations, standard-setting organizations and other agencies, for instance:

- (a) American College of Radiology, ACR Technical Standard for Electronic Practice of Medical Imaging, Res. 13-2007. In ACR Practice Guidelines and Technical Standards, pp. 1053-1067. ACR, Reston, VA, 2007.
- (b) American College of Radiology. Practice Guidelines for Digital Radiography, Res. 42-2007. In ACR Practice Guidelines and Technical Standards, pp. 23-57. ACR, Reston, VA, 2007.
- (c) European Guidelines on Quality Criteria for Diagnostic Radiographic Images. Report EUR 16260. European Commission. Luxembourg, Office for Official Publications of the European Communities, 1996.
- (d) The 1991 CEC Trial on quality criteria for diagnostic radiographic images: Detailed results and findings. Report EUR 16635. European Commission. Luxembourg, Office for Official Publications of the European Communities, 1999.
- (e) American Association of Physicists in Medicine. Assessment of Display Performance for Medical Imaging Systems. AAPM On-Line Report No. 03, Task Group 18. College Park, MD. April 2005.
- (f) U.S. Department of Health and Human Services (DHHS; NIOSH) Publication Number 2011-198. NIOSH guideline: Application of digital radiography for the detection and classification of pneumoconiosis. August 2011.

<sup>21</sup> See footnote 20.

quality, immediate production of images, and uses a lower radiation dose in comparison to CR systems. Both are acceptable for application of the ILO Classification, with appropriate attention to image quality.

## Image processing

Digital radiographic systems vary in the approaches taken to address the display quality of digital chest images. Image processing software continues to evolve. Imaging systems should comply with the standards set by their countries respective radiologic societies and professional organizations. The NIOSH Guideline “Application of Digital Radiography for the Detection and Classification of Pneumoconiosis” is a useful resource and recommends that image enhancement functions be discouraged as chest images should appear similar to traditional film screen radiographs when displayed.<sup>22</sup> No specific recommendations are made by the ILO regarding the selection of digital systems. Performance testing and monitoring should be used to evaluate the ability to produce quality images for any combination of hardware, exposure parameters and software. Facilities providing images for classification should employ a program for continual quality assurance consistent with national practices and standards. Staff at facilities that perform digital chest radiography for pneumoconiosis classification should review each image to ensure optimal quality.

## Image display

Good image quality is essential for accurate classification of digital chest radiographs. Maintenance, assessment, and optimization of the image display monitors and all other components of the digital radiographic systems should be undertaken periodically, as recommended or specified by manufacturers, professional organizations, or governmental agencies.<sup>23</sup> While classifying digital images, the ILO 2022 digitally acquired standard images should be displayed as provided, without alteration.<sup>24</sup>

## Data recording, storage, and security

Digital images should be securely archived and transferred in a manner that permits retrieval of their original appearance, in compliance with national practices and standards. Standard measures to prevent unauthorized access to data should be employed, for instance by password-protected access and rigorous security precautions for transfers through data networks.

---

22 U.S. Department of Health and Human Services (DHHS; NIOSH) Publication Number 2011-198. NIOSH guideline: Application of digital radiography for the detection and classification of pneumoconiosis. August 2011.

23 For example, see (a) and (c) in footnote 20.

24 The standard digital radiographs were chosen to demonstrate the radiographic features of the pneumoconioses, rather than technical quality.

## ▶ 7. Appendices

---

The appendices have been prepared by individual experts to assist understanding of the principles and development of the ILO Classification. They are not part of the text of the ILO International Classification of Radiographs of Pneumoconioses.



## Appendix A Notes on technical quality for chest radiographs of dust-exposed workers

Chest imaging equipment and radiographic techniques may have a significant effect on the appearance of pneumoconiotic opacities which can affect the ILO International Classification of Radiographs of Pneumoconioses. High quality chest radiographic images are required for clinical interpretation, medical screening, public health surveillance, and epidemiological research. Poor quality chest images impair readers' ability to perform an accurate ILO Classification. In some cases, it may be impossible to classify such radiographs. Section 3.1 of these *Guidelines* provides guidance for the evaluation of technical quality. Images that are classified as grade 4 are considered "unacceptable for classification purposes".

Images acquired using analog technology may be too bright, due to underexposure, causing a tendency for readers to detect higher profusions of small opacities. Analog radiographs may also be too dark, due to overexposure, causing readers to underestimate the profusion of small opacities. Experienced readers may be able to adjust their assessments of such radiographs to some extent to compensate for these technical faults, however this may not be possible. Therefore, physicians should require radiographers to obtain radiographs with optimal exposure. An optimal radiographic technique for the assessment of pneumoconioses should reveal the fine details of the parenchymal structures, demonstrate clearly the costal-pleural junctions, and show vascular markings through the cardiac shadow. It should be noted, that optimal technique for assessment of the lung parenchyma in analog radiographs, may result in suboptimal contrast and impair assessment of mediastinal structures. Good quality digital chest radiographs do not suffer from this difficulty and good quality digital images usually permit adequate evaluation of the parenchyma and mediastinum.

Chest imaging technologies continue to evolve making it impossible to provide detailed technical advice on radiographic technique and equipment. Newer digital technologies allow the radiographer to compensate for images that may previously have been assessed as "underexposed" with decreasing optical density and contrast, or "overexposed" with the opposite tendency. Physicians and radiographers should ensure that digitally acquired chest radiographs are of good quality, comply with national regulations and guidelines, and minimize unnecessary radiation exposure. Relevant information on these topics can be found in a number of specialized publications that are updated regularly. A selected bibliography can be found at the end of this appendix.

These *Guidelines* require that a decision on whether a radiograph is of good, or at least of acceptable, technical quality rests ultimately with the physician who classifies the radiograph. Therefore, a key general principle must be the establishment and maintenance of good communication between the physician and the radiographer, so that high-quality images, providing an adequate view of the pulmonary parenchyma and pleura, are obtained. The radiographer must be well trained and supervised, and must work in a climate that invites dialogue with the physician/reader. The physician must provide feedback to the radiographer to ensure improvement of any suboptimal images and should be prepared to advise on quality control for the production of chest radiographs of dust-exposed workers. Physicians and radiographers should also adhere to applicable local regulations.

## Selected bibliography

- American College of Radiology. ACR Appropriateness Criteria - Occupational Lung Diseases. Revised 2019, Resolution 40. (Reston, VA, American College of Radiology, Sept. 2019).
- American College of Radiology. ACR Practice Parameter for the Performance of Chest Radiography. Revised 2017, Resolution 2. (Reston, VA, American College of Radiology, 2017).
- American College of Radiology. ACR Practice Parameter for Digital Radiography. Revised 2017, Resolution 40. (Reston, VA, American College of Radiology, 2017).
- Commission of the European Community. European Guidelines on Quality Criteria for Diagnostic Radiographic Images, edited by J.H.E. Carmichael et al. Report OP-EUR 16260 (Luxembourg, 1996. Update in: European Guidelines on Quality Criteria for Diagnostic Radiographic Images in Pediatrics. EU publication EUR 16261; June 2000).
- Franzblau A, Kazerooni EA, Sen A et al.: Comparison of Digital Radiographs with Film Radiographs for the Classification of Pneumoconiosis. *Acad Radiol* 2009; 16:669–677.
- Guibelalde, E., et al. "Image quality and patient dose for different screen-film combinations", in *British Journal of Radiology*, Vol. 67, No. 794, Feb. 1994, pp.166–173.
- Guideline for Quality Assurance in Diagnostic Radiology - Quality Criteria for radiological diagnostic examinations - Bundesärztekammer: Association of German Medical Associations. Nov. 2007.
- Hofmann-Preiss K, Hering KG: Radiological Examinations of the Lung in Occupational Medicine – Opportunity or Risk? ASU International. July 2015.
- Holm, T.; Palmer, P.E.S.; Lehtinen, E. Manual of radiographic technique: WHO Basic Radiological System. (Geneva, World Health Organization, 1986).
- International Labour Office. "Appendix A. Equipment and technology: Guidance notes", prepared by H. Bohlig et al., in *Guidelines for the use of the ILO international classification of radiographs of pneumoconioses*. Revised edition 1980 (Geneva), pp. 21–25.
- Ravin, C.E.; Chotas, H.G. "Chest radiography", in *Radiology*, Vol. 204, No. 3 (Sept.1997), pp. 593-600.

## Appendix B Reading sheets

The reading sheets on the following pages are offered as examples of what may be used with the ILO International Classification of Radiographs of Pneumoconioses, and they are not formal part of the Classification. In some situations, other designs may be preferred for specific uses.

The sheets illustrated here make provision for recording all features described in the ILO Classification and the Abbreviated ILO Classification. Many countries use their own comparable reading sheets and reading may vary from country to country. Therefore, readers should use the reading sheet(s) recommended by their local or national jurisdiction, as applicable.

## Chest Radiograph Classification Form

Patient's Name:  Patient ID:

Birth Date:  Radiograph Date:

Note: Record your interpretation of a single radiograph by placing an "x" in the appropriate boxes on this form. Classify all appearances described in the ILO International Classification of Radiographs of Pneumoconioses or illustrated by the ILO standard radiographs. Use symbols and record comments as appropriate.

<b>1. IMAGE QUALITY</b> <input type="checkbox"/> Overexposed (dark) <input type="checkbox"/> Improper position <input type="checkbox"/> Underinflation <input type="checkbox"/> Scapula Overlay <input type="checkbox"/> 1 <input type="checkbox"/> 2 <input type="checkbox"/> 3 <input type="checkbox"/> 4 <input type="checkbox"/> Underexposed (light) <input type="checkbox"/> Poor contrast <input type="checkbox"/> Mottle <input type="checkbox"/> Other (please specify) _____ (If not grade 1, mark all boxes that apply) <input type="checkbox"/> Artifacts <input type="checkbox"/> Poor processing <input type="checkbox"/> Excessive Edge Enhancement _____																																		
<b>2A. ANY CLASSIFIABLE PARENCHYMAL ABNORMALITIES?</b>		Yes <input type="checkbox"/> Complete Sections 2B and 2C                 No <input type="checkbox"/> Proceed to Section 3A																																
<b>2B. SMALL OPACITIES</b> a. SHAPE/SIZE PRIMARY SECONDARY <table style="display: inline-table; border: none;"> <tr><td style="border: 1px solid black; padding: 2px;">p</td><td style="border: 1px solid black; padding: 2px;">s</td></tr> <tr><td style="border: 1px solid black; padding: 2px;">q</td><td style="border: 1px solid black; padding: 2px;">t</td></tr> <tr><td style="border: 1px solid black; padding: 2px;">r</td><td style="border: 1px solid black; padding: 2px;">u</td></tr> </table> <table style="display: inline-table; border: none; margin-left: 20px;"> <tr><td style="border: 1px solid black; padding: 2px;">p</td><td style="border: 1px solid black; padding: 2px;">s</td></tr> <tr><td style="border: 1px solid black; padding: 2px;">q</td><td style="border: 1px solid black; padding: 2px;">t</td></tr> <tr><td style="border: 1px solid black; padding: 2px;">r</td><td style="border: 1px solid black; padding: 2px;">u</td></tr> </table> b. ZONES R L UPPER <input type="checkbox"/> <input type="checkbox"/> MIDDLE <input type="checkbox"/> <input type="checkbox"/> LOWE <input type="checkbox"/> <input type="checkbox"/>			p	s	q	t	r	u	p	s	q	t	r	u	c. PROFUSION <table style="display: inline-table; border: none;"> <tr><td style="border: 1px solid black; padding: 2px;">0/-</td><td style="border: 1px solid black; padding: 2px;">0/0</td><td style="border: 1px solid black; padding: 2px;">0/1</td></tr> <tr><td style="border: 1px solid black; padding: 2px;">1/0</td><td style="border: 1px solid black; padding: 2px;">1/1</td><td style="border: 1px solid black; padding: 2px;">1/2</td></tr> <tr><td style="border: 1px solid black; padding: 2px;">2/1</td><td style="border: 1px solid black; padding: 2px;">2/2</td><td style="border: 1px solid black; padding: 2px;">2/3</td></tr> <tr><td style="border: 1px solid black; padding: 2px;">3/2</td><td style="border: 1px solid black; padding: 2px;">3/3</td><td style="border: 1px solid black; padding: 2px;">3/+</td></tr> </table>		0/-	0/0	0/1	1/0	1/1	1/2	2/1	2/2	2/3	3/2	3/3	3/+						
p	s																																	
q	t																																	
r	u																																	
p	s																																	
q	t																																	
r	u																																	
0/-	0/0	0/1																																
1/0	1/1	1/2																																
2/1	2/2	2/3																																
3/2	3/3	3/+																																
<b>2C. LARGE OPACITIES</b> SIZE <input type="checkbox"/> O <input type="checkbox"/> A <input type="checkbox"/> B <input type="checkbox"/> C Proceed to Section 3A																																		
<b>3A. ANY CLASSIFIABLE PLEURAL ABNORMALITIES?</b>		Yes <input type="checkbox"/> Complete Sections 3B and 3C                 No <input type="checkbox"/> Proceed to Section 4A																																
<b>3B. PLEURAL PLAQUES (mark site, calcification, extent, and width)</b> <table style="width:100%; border-collapse: collapse;"> <tr> <th style="width: 15%;">Chest wall</th> <th style="width: 15%;">Site</th> <th style="width: 15%;">Calcification</th> <th style="width: 25%;">Extent (chest wall; combined for in profile and face on)</th> <th style="width: 30%;">Width (in profile only) (3mm minimum width required)</th> </tr> <tr> <td>In profile</td> <td><input type="checkbox"/> O <input type="checkbox"/> R <input type="checkbox"/> L</td> <td><input type="checkbox"/> O <input type="checkbox"/> R <input type="checkbox"/> L</td> <td>Up to 1/4 of lateral chest wall = 1</td> <td>3 to 5 mm = a</td> </tr> <tr> <td>Face on</td> <td><input type="checkbox"/> O <input type="checkbox"/> R <input type="checkbox"/> L</td> <td><input type="checkbox"/> O <input type="checkbox"/> R <input type="checkbox"/> L</td> <td>1/4 to 1/2 of lateral chest wall = 2</td> <td>5 to 10 mm = b</td> </tr> <tr> <td>Diaphragm</td> <td><input type="checkbox"/> O <input type="checkbox"/> R <input type="checkbox"/> L</td> <td><input type="checkbox"/> O <input type="checkbox"/> R <input type="checkbox"/> L</td> <td>&gt; 1/2 of lateral chest wall = 3</td> <td>&gt; 10 mm = c</td> </tr> <tr> <td>Other site(s)</td> <td><input type="checkbox"/> O <input type="checkbox"/> R <input type="checkbox"/> L</td> <td><input type="checkbox"/> O <input type="checkbox"/> R <input type="checkbox"/> L</td> <td><input type="checkbox"/> O <input type="checkbox"/> R <input type="checkbox"/> L</td> <td><input type="checkbox"/> O <input type="checkbox"/> L</td> </tr> <tr> <td></td> <td></td> <td></td> <td><input type="checkbox"/> 1 <input type="checkbox"/> 2 <input type="checkbox"/> 3</td> <td><input type="checkbox"/> a <input type="checkbox"/> b <input type="checkbox"/> c</td> </tr> </table>					Chest wall	Site	Calcification	Extent (chest wall; combined for in profile and face on)	Width (in profile only) (3mm minimum width required)	In profile	<input type="checkbox"/> O <input type="checkbox"/> R <input type="checkbox"/> L	<input type="checkbox"/> O <input type="checkbox"/> R <input type="checkbox"/> L	Up to 1/4 of lateral chest wall = 1	3 to 5 mm = a	Face on	<input type="checkbox"/> O <input type="checkbox"/> R <input type="checkbox"/> L	<input type="checkbox"/> O <input type="checkbox"/> R <input type="checkbox"/> L	1/4 to 1/2 of lateral chest wall = 2	5 to 10 mm = b	Diaphragm	<input type="checkbox"/> O <input type="checkbox"/> R <input type="checkbox"/> L	<input type="checkbox"/> O <input type="checkbox"/> R <input type="checkbox"/> L	> 1/2 of lateral chest wall = 3	> 10 mm = c	Other site(s)	<input type="checkbox"/> O <input type="checkbox"/> R <input type="checkbox"/> L	<input type="checkbox"/> O <input type="checkbox"/> R <input type="checkbox"/> L	<input type="checkbox"/> O <input type="checkbox"/> R <input type="checkbox"/> L	<input type="checkbox"/> O <input type="checkbox"/> L				<input type="checkbox"/> 1 <input type="checkbox"/> 2 <input type="checkbox"/> 3	<input type="checkbox"/> a <input type="checkbox"/> b <input type="checkbox"/> c
Chest wall	Site	Calcification	Extent (chest wall; combined for in profile and face on)	Width (in profile only) (3mm minimum width required)																														
In profile	<input type="checkbox"/> O <input type="checkbox"/> R <input type="checkbox"/> L	<input type="checkbox"/> O <input type="checkbox"/> R <input type="checkbox"/> L	Up to 1/4 of lateral chest wall = 1	3 to 5 mm = a																														
Face on	<input type="checkbox"/> O <input type="checkbox"/> R <input type="checkbox"/> L	<input type="checkbox"/> O <input type="checkbox"/> R <input type="checkbox"/> L	1/4 to 1/2 of lateral chest wall = 2	5 to 10 mm = b																														
Diaphragm	<input type="checkbox"/> O <input type="checkbox"/> R <input type="checkbox"/> L	<input type="checkbox"/> O <input type="checkbox"/> R <input type="checkbox"/> L	> 1/2 of lateral chest wall = 3	> 10 mm = c																														
Other site(s)	<input type="checkbox"/> O <input type="checkbox"/> R <input type="checkbox"/> L	<input type="checkbox"/> O <input type="checkbox"/> R <input type="checkbox"/> L	<input type="checkbox"/> O <input type="checkbox"/> R <input type="checkbox"/> L	<input type="checkbox"/> O <input type="checkbox"/> L																														
			<input type="checkbox"/> 1 <input type="checkbox"/> 2 <input type="checkbox"/> 3	<input type="checkbox"/> a <input type="checkbox"/> b <input type="checkbox"/> c																														
<b>3C. COSTOPHRENIC ANGLE OBLITERATION</b>		<input type="checkbox"/> R <input type="checkbox"/> L Proceed to Section 3D                 No <input type="checkbox"/> Proceed to Section 4A																																
<b>3D. DIFFUSE PLEURAL PLAQUES THICKENING (mark site, calcification, extent, and width)</b> <table style="width:100%; border-collapse: collapse;"> <tr> <th style="width: 15%;">Chest wall</th> <th style="width: 15%;">Site</th> <th style="width: 15%;">Calcification</th> <th style="width: 25%;">Extent (chest wall; combined for in profile and face on)</th> <th style="width: 30%;">Width (in profile only) (3mm minimum width required)</th> </tr> <tr> <td>In profile</td> <td><input type="checkbox"/> O <input type="checkbox"/> R <input type="checkbox"/> L</td> <td><input type="checkbox"/> O <input type="checkbox"/> R <input type="checkbox"/> L</td> <td>Up to 1/4 of lateral chest wall = 1</td> <td>3 to 5 mm = a</td> </tr> <tr> <td>Face on</td> <td><input type="checkbox"/> O <input type="checkbox"/> R <input type="checkbox"/> L</td> <td><input type="checkbox"/> O <input type="checkbox"/> R <input type="checkbox"/> L</td> <td>1/4 to 1/2 of lateral chest wall = 2</td> <td>5 to 10 mm = b</td> </tr> <tr> <td></td> <td></td> <td></td> <td>&gt; 1/2 of lateral chest wall = 3</td> <td>&gt; 10 mm = c</td> </tr> <tr> <td></td> <td></td> <td></td> <td><input type="checkbox"/> O <input type="checkbox"/> R <input type="checkbox"/> L</td> <td><input type="checkbox"/> O <input type="checkbox"/> L</td> </tr> <tr> <td></td> <td></td> <td></td> <td><input type="checkbox"/> 1 <input type="checkbox"/> 2 <input type="checkbox"/> 3</td> <td><input type="checkbox"/> a <input type="checkbox"/> b <input type="checkbox"/> c</td> </tr> </table>					Chest wall	Site	Calcification	Extent (chest wall; combined for in profile and face on)	Width (in profile only) (3mm minimum width required)	In profile	<input type="checkbox"/> O <input type="checkbox"/> R <input type="checkbox"/> L	<input type="checkbox"/> O <input type="checkbox"/> R <input type="checkbox"/> L	Up to 1/4 of lateral chest wall = 1	3 to 5 mm = a	Face on	<input type="checkbox"/> O <input type="checkbox"/> R <input type="checkbox"/> L	<input type="checkbox"/> O <input type="checkbox"/> R <input type="checkbox"/> L	1/4 to 1/2 of lateral chest wall = 2	5 to 10 mm = b				> 1/2 of lateral chest wall = 3	> 10 mm = c				<input type="checkbox"/> O <input type="checkbox"/> R <input type="checkbox"/> L	<input type="checkbox"/> O <input type="checkbox"/> L				<input type="checkbox"/> 1 <input type="checkbox"/> 2 <input type="checkbox"/> 3	<input type="checkbox"/> a <input type="checkbox"/> b <input type="checkbox"/> c
Chest wall	Site	Calcification	Extent (chest wall; combined for in profile and face on)	Width (in profile only) (3mm minimum width required)																														
In profile	<input type="checkbox"/> O <input type="checkbox"/> R <input type="checkbox"/> L	<input type="checkbox"/> O <input type="checkbox"/> R <input type="checkbox"/> L	Up to 1/4 of lateral chest wall = 1	3 to 5 mm = a																														
Face on	<input type="checkbox"/> O <input type="checkbox"/> R <input type="checkbox"/> L	<input type="checkbox"/> O <input type="checkbox"/> R <input type="checkbox"/> L	1/4 to 1/2 of lateral chest wall = 2	5 to 10 mm = b																														
			> 1/2 of lateral chest wall = 3	> 10 mm = c																														
			<input type="checkbox"/> O <input type="checkbox"/> R <input type="checkbox"/> L	<input type="checkbox"/> O <input type="checkbox"/> L																														
			<input type="checkbox"/> 1 <input type="checkbox"/> 2 <input type="checkbox"/> 3	<input type="checkbox"/> a <input type="checkbox"/> b <input type="checkbox"/> c																														
<b>4A. ANY OTHER ABNORMALITIES?</b>		Yes <input type="checkbox"/> Complete Sections 4B, 4C                 No <input type="checkbox"/> Proceed to Section 5																																
<b>4B. OTHER SYMBOLS (OBLIGATORY)</b> <input type="checkbox"/> aa <input type="checkbox"/> at <input type="checkbox"/> ax <input type="checkbox"/> bu <input type="checkbox"/> ca <input type="checkbox"/> cg <input type="checkbox"/> cn <input type="checkbox"/> co <input type="checkbox"/> cp <input type="checkbox"/> cv <input type="checkbox"/> di <input type="checkbox"/> ef <input type="checkbox"/> em <input type="checkbox"/> es <input type="checkbox"/> fr <input type="checkbox"/> hi <input type="checkbox"/> ho <input type="checkbox"/> id <input type="checkbox"/> ih <input type="checkbox"/> kl <input type="checkbox"/> me <input type="checkbox"/> pa <input type="checkbox"/> pb <input type="checkbox"/> pi <input type="checkbox"/> px <input type="checkbox"/> ra <input type="checkbox"/> rp <input type="checkbox"/> tb <input type="checkbox"/> OD If other diseases or significant abnormalities, findings must be recovered on reverse. Date Physician or Worker notified? _____																																		
<b>4C. Should worker see personal physician because of findings in section 4?</b> Yes <input type="checkbox"/> No <input type="checkbox"/> <input type="text"/>																																		

5. Radiology Facility  Reading Type

Ordering Physician  Classifying Physician's Name and Signature \_\_\_\_\_

Reading Date

Classification Purpose

### Reading Sheet for the Abbreviated ILO Classification

Reader Code

Radiograph Identifier

Date of Reading

-   -

Date of Radiograph

-   -

#### Technical Quality

Grade 1, 2, 3, or 4

Mark appropriate box

1  2  3  4

**Comment** on technical quality:

If the grade is not 1 – **comments** required here:

#### Parenchymal Abnormalities

##### Small opacities

Predominant shape and size  
(Consult standard radiographs)

p, q, r, s, t, or u  
Mark only one box

p	s
q	t
r	u

Profusion (4-point scale)

(Consult standard radiographs)

Mark profusion category

0  1  2  3

##### Large opacities

Mark 0 for none or mark A, B, or C

0  A  B  C

##### Pleural Abnormalities

Yes  No

If "No" go to \*Symbols

0=None R=Right L=Left)

Pleural thickening - PT

O  R  L

Pleural calcification - PC

O  R  L

#### \* Symbols

Yes  No

aa at ax bu ca cg cn co cp cv di ef em es  
fr hi ho id ih kl me pa pb pi px ra rp tb od

(Circle as appropriate; if **od** is circled,  
**comments** must be made below)

#### Comments

Yes  No

## Appendix C Description of the ILO standard digital images

The 2022 digital ILO International Classification of Radiographs of Pneumoconioses is accompanied by 23 digitally acquired images. Two of them illustrate category **0/0** profusion of small opacities. Fifteen others define small- opacity profusion categories (**1/1**, **2/2** and **3/3**), and some of the shapes and sizes of these opacities (**p**, **q**, **r**, **s**, and **t**). One composite four quadrant digitized image defines small-opacity profusions categories for **u** opacities. One standard digital image defines the lower limit of costophrenic angle blunting and a second standard digital image demonstrates in profile and face on pleural abnormalities found on the chest wall and diaphragm, including characteristics of calcification and diffuse pleural thickening. Large opacities (categories **A**, **B** and **C**), and an example of pleural findings are shown on four additional example radiographs. These radiographs are described in the following table using the conventions defined in the preceding text and including comments. The presence of small opacities is shown by a ✓ in the boxes symbolizing the zones of the lungs, as follows:

	Right	Left
Upper	<input type="checkbox"/>	<input type="checkbox"/>
Middle	<input type="checkbox"/>	<input type="checkbox"/>
Lower	<input type="checkbox"/>	<input type="checkbox"/>

The radiographs that define the small-opacity profusion categories are newly acquired digital images that have been selected to preserve continuity and consistency in the ILO Classification. As noted in footnote 3 on page 3, the standard digital images were chosen to demonstrate the radiographic features of the pneumoconioses, rather than to demonstrate technical quality.

The descriptions of the radiographs in the following table are the consensus views of a group of experts who selected these standard digital images in September of 2018. Judgment about the technical quality of the radiographs reflects familiarity with current optimal techniques.

Descriptions of pleural abnormalities now follow the modified conventions that are defined in these *Guidelines* (section 3.3). The comments in the right-hand column of the table include some additional observations by the reviewers.

## ► Description of the ILO standard digital images

Standard digital image (ILO 2022)	Technical quality	Parenchymal abnormalities				Pleural abnormalities						Symbols	Comments
		Profusion	Shape and size	Zones		Large opacities	Chest wall		Costophrenic angle obliteration	Diaphragm	Calcification		
				R	L		Plaques (localized pleural thickening)	Diffuse pleural thickening					
0/0 (example 1)	1	0/0	-	-	No	No	No	No	No	No	No	None	Vascular pattern is well illustrated.
0/0 (example 2)	2	0/0	-	-	No	No	No	No	No	No	No	None	Quality 2: Scapular overlay. Vascular pattern and normal end-on vessels are well illustrated.
1/1 p/p	2	1/1	p/p	R ✓ ✓ ✓	L ✓ ✓ ✓	A	No	No	No	No	No	tb	Quality 2: Minimal scapular overlay. Note the A-sized large opacities in right upper zone and left upper zone overlying the second anterolateral rib. Note the symbol for tuberculosis has been selected recognizing the possibility that TB may have contributed to these findings.
2/2 p/p	2	2/2	p/p	R ✓ ✓ ✓	L ✓ ✓ ✓	No	No	No	No	No	No	None	Quality 2: Slightly reduced contrast in upper zones laterally.
3/3 p/p	2	3/3	p/p	R ✓ ✓ ✓	L ✓ ✓ ✓	No	No	No	No	No	No	fr hi ih	Quality 2: Improper position with left scapular overlay; electrode artifact.
1/1 q/q	1	1/1	q/q	R ✓ ✓ □	L ✓ ✓ □	No	No	No	No	No	No	es	

(Continued)

► Description of the ILO standard digital images (continued)

Standard digital image (ILO 2022)	Technical quality	Parenchymal abnormalities				Pleural abnormalities					Symbols	Comments	
		Profusion	Shape and size	Zones		Large opacities	Chest wall		Costophrenic angle obliteration	Diaphragm			Calcification
				R	L		Plaques (localized pleural thickening)	Diffuse pleural thickening					
2/2 q/q	2	2/2	q/q	<input checked="" type="checkbox"/>	<input checked="" type="checkbox"/>	No	No	No	No	No	No	None	Quality 2: Bilateral scapular overlay, right costophrenic angle cut off, clothing artifact in both apices.
3/3 q/q	2	3/3	q/q	<input checked="" type="checkbox"/>	<input checked="" type="checkbox"/>	No	No	No	No	No	No	None	Quality 2: Apices are cut off, mottle.
1/1 r/r	2	1/1	r/r	<input checked="" type="checkbox"/>	<input checked="" type="checkbox"/>	No	No	No	No	No	No	aa em bu di	Quality 2: Scapular overlay, overexposed. Post-operative hemiarthroplasty, nipple markers present bilaterally.
2/2 r/r	2	2/2	r/r	<input checked="" type="checkbox"/>	<input checked="" type="checkbox"/>	No	No	No	No	No	No	ax	Quality 2: Scapular overlay. Coalescence of small opacities in upper right lung zone.
3/3 r/r	1	3/3	r/r	<input checked="" type="checkbox"/>	<input checked="" type="checkbox"/>	No	No	No	No	No	No	ax pi	Coalescence of small opacities in right middle zone.
1/1 s/s	2	1/1	s/s	<input type="checkbox"/>	<input type="checkbox"/>	No	No	No	No	No	No	aa	Quality 2: Poor contrast issues, scapular overlay.

(Continued)



► Description of the ILO standard digital images (continued)

Standard digital image (ILO 2022)	Technical quality	Parenchymal abnormalities				Pleural abnormalities					Symbols	Comments	
		Profusion	Shape and size	Zones		Large opacities	Chest wall		Costophrenic angle obliteration	Diaphragm			Calcification
				R	L		Plaques (localized pleural thickening)	Diffuse pleural thickening					
2/2 s/s	1	2/2	s/s	<input type="checkbox"/> R <input checked="" type="checkbox"/> <input checked="" type="checkbox"/>	<input type="checkbox"/> L <input checked="" type="checkbox"/> <input checked="" type="checkbox"/>	No	No	No	No	No	No	pa	
3/3 s/s	2	3/3	s/s	<input checked="" type="checkbox"/> R <input checked="" type="checkbox"/> <input checked="" type="checkbox"/>	<input checked="" type="checkbox"/> L <input checked="" type="checkbox"/> <input checked="" type="checkbox"/>	No	No	No	No	No	No	ho id ih	Quality 2: Slight scapular overlay.
1/1 t/t	2	1/1	t/t	<input type="checkbox"/> R <input checked="" type="checkbox"/> <input checked="" type="checkbox"/>	<input type="checkbox"/> L <input checked="" type="checkbox"/> <input checked="" type="checkbox"/>	No	Yes <input checked="" type="checkbox"/> R <input type="checkbox"/> L In Profile & Face on	No	No	Yes <input checked="" type="checkbox"/> R <input type="checkbox"/> L	Yes <input checked="" type="checkbox"/> R <input type="checkbox"/> L Diaphragm	None	Quality 2: Scapular overlay, slightly overexposed.
2/2 t/t	2	2/2	t/t	<input type="checkbox"/> R <input checked="" type="checkbox"/> <input checked="" type="checkbox"/>	<input type="checkbox"/> L <input checked="" type="checkbox"/> <input checked="" type="checkbox"/>	No	Yes <input checked="" type="checkbox"/> R <input checked="" type="checkbox"/> L In Profile	No	No	Yes <input checked="" type="checkbox"/> R <input type="checkbox"/> L	Yes <input checked="" type="checkbox"/> R <input type="checkbox"/> L Diaphragm	aa id ih	Quality 2: Poor contrast.
3/3 t/s	2	3/3	t/s	<input type="checkbox"/> R <input checked="" type="checkbox"/> <input checked="" type="checkbox"/>	<input type="checkbox"/> L <input checked="" type="checkbox"/> <input checked="" type="checkbox"/>	No	No	Yes <input type="checkbox"/> R <input checked="" type="checkbox"/> L In Profile	Yes <input type="checkbox"/> R <input checked="" type="checkbox"/> L	No	No	bu ho cg id co ih em	Quality 2: Scapular overlay, slight left anterior rotation.
0/0	-	-	-	-	-	-	-	-	-	-	-	-	This composite radiograph taken from the ILO 2011-D digitized standards illustrates central subcategories of profusion of small opacities classifiable for shape and size <b>u/u</b> .
1/1 u/u	-	-	-	-	-	-	-	-	-	-	-	-	
2/2 u/u	-	-	-	-	-	-	-	-	-	-	-	-	
3/3 u/u	-	-	-	-	-	-	-	-	-	-	-	-	

(Continued)

► Description of the ILO standard digital images (continued)

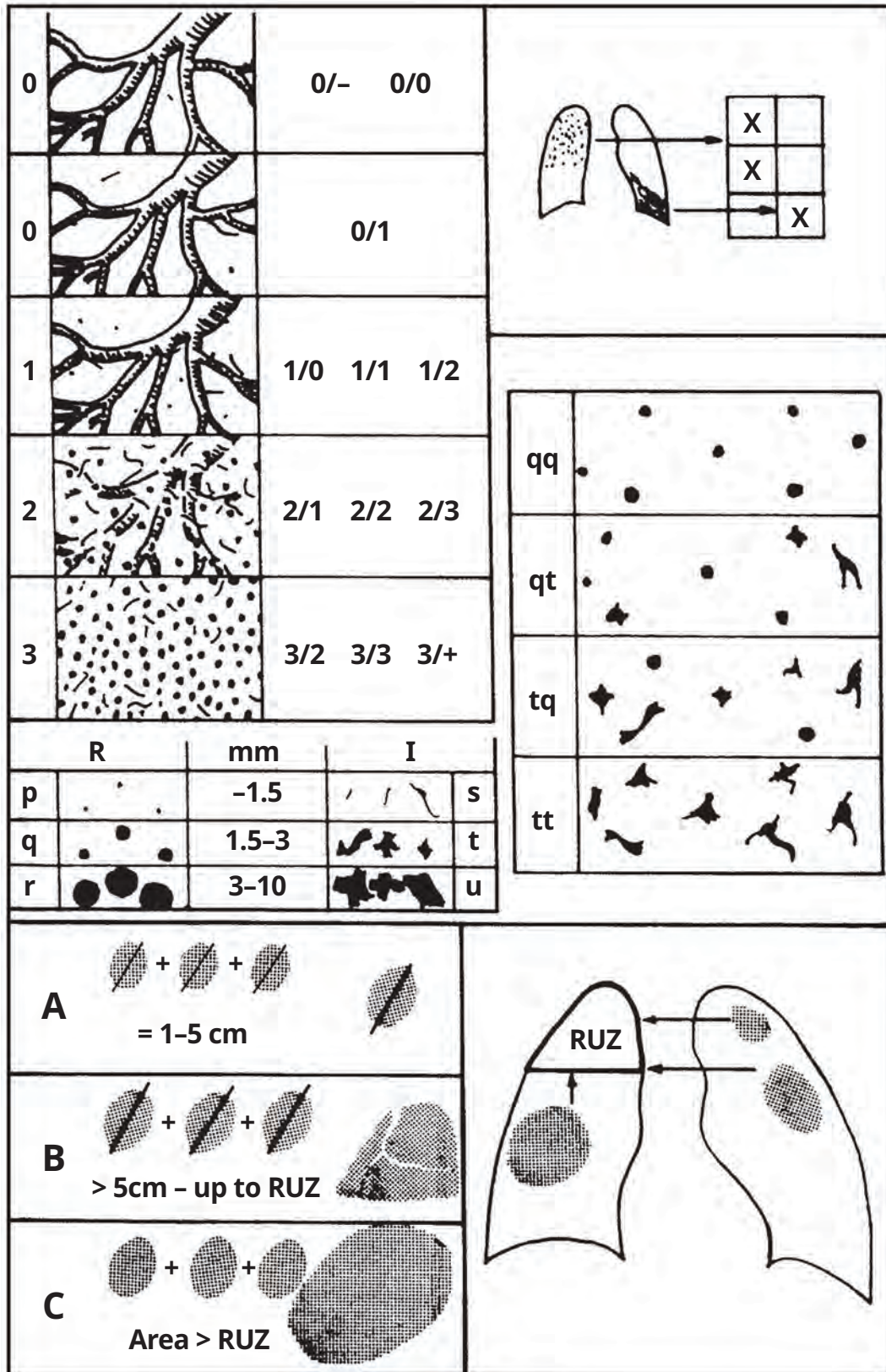
Standard digital image (ILO 2022)	Technical quality	Parenchymal abnormalities				Pleural abnormalities					Symbols	Comments	
		Profusion	Shape and size	Zones		Large opacities	Chest wall		Costophrenic angle obliteration	Diaphragm			Calcification
				R	L		Plaques (localized pleural thickening)	Diffuse pleural thickening					
A	2	2/3	q/r	<input checked="" type="checkbox"/> R <input checked="" type="checkbox"/> L	A	No	No	No	No	No	aa ax	Quality 2: Scapular overlay. A-sized large opacity in upper right zone. Coalescence of small opacities in upper right lung zone.	
B	1	2/3	q/r	<input checked="" type="checkbox"/> R <input checked="" type="checkbox"/> L	B	No	No	No	No	No	ax bu di	Large opacities are present in both upper zones with the sum of their longest dimensions indicative of size B.	
C	2	3/+	r/r	<input checked="" type="checkbox"/> R <input checked="" type="checkbox"/> L	C	No	No	No	No	No	di pb id ih	Quality 2: Improper position, scapular overlay, horizontal streak artifact.	
Pleural	2	-	-	-	No	Yes R L <input type="checkbox"/> <input checked="" type="checkbox"/> In Profile & Face On	Yes R L <input checked="" type="checkbox"/> <input type="checkbox"/> In Profile	Yes R L <input checked="" type="checkbox"/> <input type="checkbox"/>	Yes R L <input type="checkbox"/> <input checked="" type="checkbox"/>	Yes R L <input checked="" type="checkbox"/> <input checked="" type="checkbox"/>	aa me	Quality 2: Mottle. Consider mesothelioma. Note diffuse pleural thickening.	
Pleural, costophrenic angle obliteration	2	-	-	-	No	Yes R L <input type="checkbox"/> <input checked="" type="checkbox"/> In Profile & Face On	Yes R L <input checked="" type="checkbox"/> <input type="checkbox"/> In Profile & Face On	Yes R L <input checked="" type="checkbox"/> <input type="checkbox"/>	Yes R L <input checked="" type="checkbox"/> <input checked="" type="checkbox"/>	Yes R L <input checked="" type="checkbox"/> <input checked="" type="checkbox"/>	None	Quality 2: Poor contrast, mottle. Note calcification in the right mediastinal pleural reflection. <b>This image defines the amount of blunting necessary to recognize an abnormal CP angle.</b>	

## Appendix D Diagrams

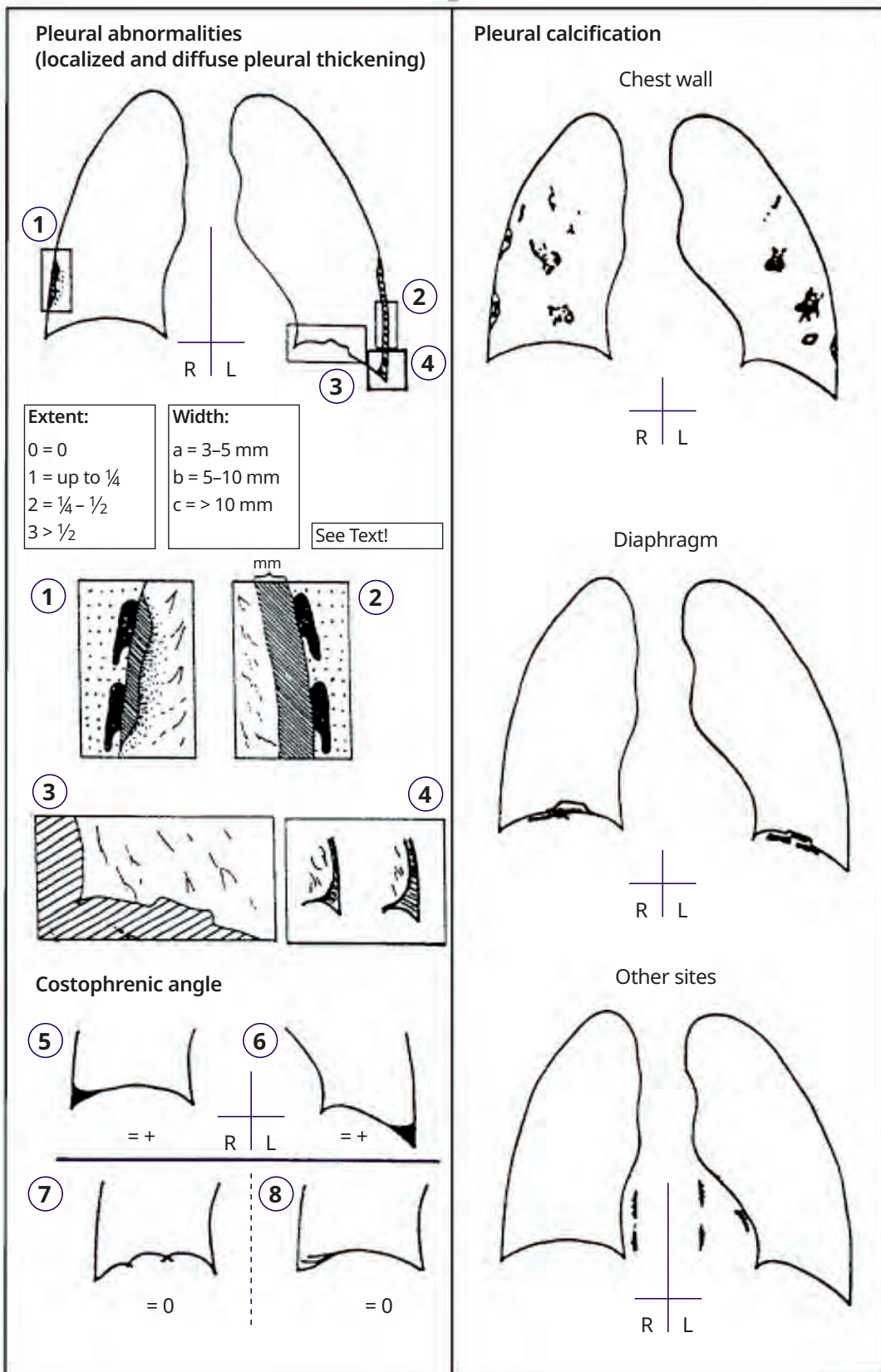
The diagrams on the following pages represent illustrations of radiographic features that are included in the Classification. Those features are defined in the text of these *Guidelines* and by the appearances on the standard radiographs. The diagrams are intended to serve as pictorial reminders, but they are not a substitute for the standard radiographs or the written text.

Diagrams that represent symbols do not illustrate all the manifestations of the conditions defined by these symbols, for example **ca** (carcinoma), **cg** (calcified granuloma), **od** (other disease). The two drawings of appearances classifiable as **od** in this appendix represent lobar pneumonia and aspergilloma, goiter and hiatal hernia.

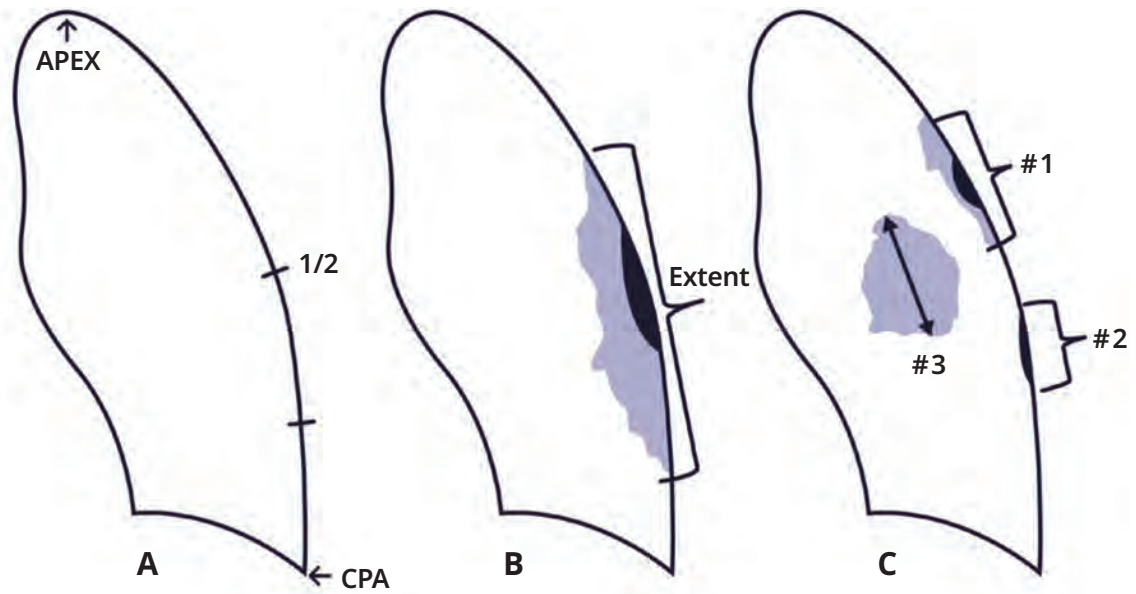
► Figure 1. Illustrations describing range of small opacity profusion, affected zones, examples of small opacity shape and size, and categories of large opacities.





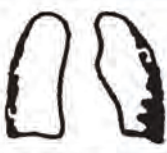



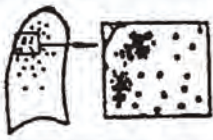
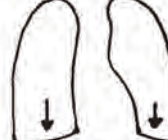


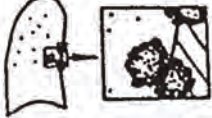





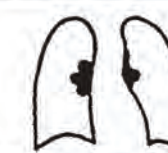

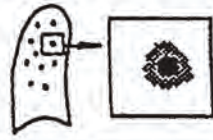



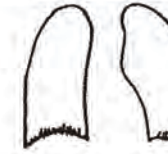


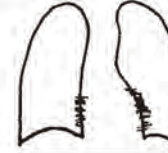


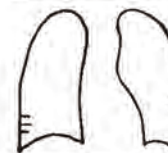

► Figure 2. Illustrations depicting a range of pleural abnormalities.



▶ Figure 3. Pleural plaques, face-on, mixed profile and face-on-extent.



► Figure 4. Diagrams representing the other symbols.

aa		di		me	
at		ef		pa	
ax		em		pb	
bu		es		pi	
ca		fr		px	
cg		hi		ra	
cn		ho		rp	
co		id		tb	
cp		ih		od	
cv		kl		od	

## Appendix E Summary of the details of the ILO standard digital images

Features	Codes	Definitions
<b>Technical quality</b>	1	Good.
	2	Acceptable, with no technical defect likely to impair classification of the radiograph for pneumoconiosis.
	3	Acceptable, with some technical defect but still adequate for classification purposes.
	4	Unacceptable for classification purposes.
		If technical quality is not grade 1, a comment must be made about the technical defect.
<b>Parenchymal abnormalities</b>		
Small opacities		
Profusion	0/- 0/0 0/1 1/0 1/1 1/2 2/1 2/2 2/3 3/2 3/3 3/+	The category of profusion is based on assessment of the concentration of opacities by comparison with the standard radiographs. Category 0: small opacities absent or less profuse than category 1. Categories 1, 2, and 3 represent increasing profusion of small opacities, as defined by the corresponding standard radiographs.
Zones	RU LU RM LM RL LL	The zones in which the opacities are seen are recorded. The right (R) and left (L) thorax are both divided into three zones: upper (U), middle (M), and lower (L). The category of profusion is determined by considering the profusion as a whole over the affected zones of the lung and by comparing this with the standard radiographs. See footnote 5 in Chapter 3.
Shape and size		
- rounded	p/p q/q r/r	The letters p, q, and r denote the presence of small rounded opacities, with three sizes defined by the appearances on the standard radiographs: p = diameter up to about 1.5 mm; q = diameter exceeding about 1.5 mm and up to about 3 mm; r = diameter exceeding about 3 mm and up to about 10 mm.
- irregular	s/s t/t u/u	The letters s, t, and u denote the presence of small irregular opacities, with three sizes defined by the appearances on the standard radiographs: s = width up to about 1.5 mm; t = width exceeding about 1.5 mm and up to about 3 mm; u = width exceeding about 3 mm and up to about 10 mm.
- mixed	p/s p/t p/u p/q p/r q/s q/t q/u q/p q/r r/s r/t r/u r/p r/q s/p s/q s/r s/t s/u t/p t/q t/r t/s t/u u/p u/q u/r u/s u/t	For mixed shapes (or sizes) of small opacities, the predominant (primary) shape and size is recorded first. The presence of a significant number of another shape and size (secondary) is recorded after the oblique stroke.

(Continued)



Features	Codes	Definitions
Large opacities	0 A B C (0 = no large opacities)	<p>One large opacity is defined as an opacity having the longest dimension exceeding 10 mm. Categories of large opacities are defined below. These definitions take precedence over the examples of large opacities illustrated on standard radiographs.</p> <p>Category A: one large opacity having the longest dimension up to about 50 mm, or several large opacities with the sum of their longest dimensions not exceeding about 50 mm.</p> <p>Category B: one large opacity having the longest dimension exceeding 50 mm but not exceeding the equivalent area of the right upper zone, or several large opacities with the sum of their longest dimensions exceeding 50 mm but not exceeding the equivalent area of the right upper zone.</p> <p>Category C: one large opacity which exceeds the equivalent area of the right upper zone, or several large opacities which when combined exceed the equivalent area of the right upper zone.</p>
<b>Pleural abnormalities</b>		
Pleural plaques (localized pleural thickening)		<p>Three types of pleural abnormalities are recognized: pleural plaques (localized pleural thickening), costophrenic angle obliteration, and diffuse pleural thickening. These abnormalities are recorded as absent (0) or present. If present they are recorded separately for the right (R) and left (L) sides.</p>
<p>Chest wall</p> <p>in-profile</p> <p>– calcification</p> <p>– width (optional)</p> <p>face-on</p> <p>– calcification</p> <p>extent</p>	<p>0 R L</p> <p>0 R L</p> <p>R(a, b, c) L(a, b, c)</p> <p>0 R L</p> <p>0 R L</p> <p>R(1, 2, 3) L(1, 2, 3)</p>	<p>Pleural plaques on the chest wall are recorded separately as “in-profile” or “face-on”. A minimum width of about 3 mm is required for an in-profile plaque to be recorded as present. The presence or absence of calcification is also noted separately for in-profile and face-on plaques. When calcification is seen, a plaque is also recorded as present at that site. For optional recording of width of an in-profile plaque, see footnote 9 in Chapter 3.</p> <p>Extent refers to the total length of involvement with respect to the projection of the lateral chest wall for in-profile and face-on plaques combined:</p> <p>1 = total length up to ¼ of the projection of the lateral chest wall;</p> <p>2 = total length exceeding ¼ and up to ½ of the projection of the lateral chest wall; and</p> <p>3 = total length exceeding ½ of the projection of the lateral chest wall.</p>
<p>Diaphragm</p> <p>– calcification</p>	<p>0 R L</p> <p>0 R L</p>	<p>When calcification is seen, a plaque is also recorded at that site.</p>
<p>Other sites</p> <p>– calcification</p>	<p>0 R L</p> <p>0 R L</p>	<p>Other sites include the mediastinal pleura in the para-spinal or para-cardiac locations.</p> <p>When calcification is seen, a plaque is also recorded at that site.</p>
Costophrenic angle obliteration	0 R L	<p>The lower limit for costophrenic angle obliteration is defined by the “<b>Pleural, costophrenic angle obliteration</b>” standard radiograph.</p>
<p>Diffuse pleural thickening</p> <p>Chest wall</p> <p>in-profile</p> <p>– calcification</p> <p>– width (optional)</p> <p>face-on</p> <p>– calcification</p> <p>extent</p>	<p>0 R L</p> <p>0 R L</p> <p>R(a, b, c) L(a, b, c)</p> <p>0 R L</p> <p>0 R L</p> <p>R(1, 2, 3) L(1, 2, 3)</p>	<p>Diffuse pleural thickening extending up the lateral chest wall is recorded only in the presence of an obliterated costophrenic angle. If present, diffuse pleural thickening is recorded separately for the right and left sides when seen in-profile and when seen face-on. The presence or absence of calcification is noted in both cases. For optional recording of width of in-profile diffuse pleural thickening, see footnote 9 in Chapter 3.</p> <p>Extent refers to the total length of involvement with respect to the projection of the lateral chest wall for in-profile and face-on varieties combined:</p> <p>1 = total length up to ¼ of the projection of the lateral chest wall;</p> <p>2 = total length exceeding ¼ and up to ½ of the projection of the lateral chest wall; and</p> <p>3 = total length exceeding ½ of the projection of the lateral chest wall.</p>

(Continued)

Features	Codes	Definitions
<b>Symbols</b>		The definition of each symbol should be understood as being preceded by an introductory qualifying word or phrase such as "changes indicative of", "opacities suggestive of", or "suspect".
	aa	atherosclerotic aorta
	at	significant apical pleural thickening
	ax	coalescence of small opacities
	bu	bullae
	ca	cancer: thoracic malignancies excluding mesothelioma
	cg	calcified non-pneumoconiotic nodules (e.g. granuloma) or nodes
	cn	calcification in small pneumoconiotic opacities
	co	abnormality of cardiac size or shape
	cp	cor pulmonale
	cv	cavity
	di	marked distortion of an intrathoracic structure
	ef	pleural effusion
	em	emphysema
	es	eggshell calcification of hilar or mediastinal lymph nodes
	fr	fractured rib(s) (acute or healed)
	hi	enlargement of non-calcified hilar or mediastinal lymph nodes
	ho	honeycomb lung
	id	ill-defined diaphragm border
	ih	ill-defined heart border
	kl	septal (Kerley) lines
	me	mesothelioma
	pa	plate atelectasis
	pb	parenchymal bands
	pi	pleural thickening of an interlobar fissure
	px	pneumothorax
	ra	rounded atelectasis
	rp	rheumatoid pneumoconiosis
	tb	tuberculosis
	od	other disease or significant abnormality
<b>Comments</b>	Y (= Yes) N (= No)	In addition to comments about the technical quality of the radiograph (see above), comments are also required if the symbol <b>od</b> (other disease) is recorded, and to identify any part of the reading of a chest radiograph which is believed by a reader to be probably or certainly not dust related. Comments should also be recorded to provide other relevant information.

## Appendix F Participants in the ILO convened meeting leading to the 2022 revised edition of the digital ILO International Classification of Radiographs of Pneumoconioses

**ILO International Training Centre, Turin, Italy, 11–13 September 2018**

### Participants

Dr Michael D. Attfield, National Institute for Occupational Safety and Health (NIOSH), Morgantown, West Virginia, United States

Dr Enrico Cardona, Civita Castellana, Italy

Dr Junqiang Chen, Hangzhou Medical College, Zhejiang Academy of Medical Sciences, Hangzhou, China

Dr Robert A.C. Cohen, National Institute for Occupational Safety and Health (NIOSH), Morgantown, West Virginia, United States

Dr Cara N. Halldin, National Institute for Occupational Safety and Health (NIOSH), Morgantown, West Virginia, United States

Dr Karina Hannerose Hofmann-Preiss, Møehrendorf, Germany

Dr Kurt G. Hering, Knappschafts Krankenhaus, Dortmund, Germany

Dr Rita Leonori, Health Local Unit of Viterbo, Viterbo, Italy

Dr Yukinori Kusaka, University of Fukui, Japan

Dr Ling Mao, Shanghai Pulmonary Hospital, Shanghai, China

Dr Carlos Eduardo Orduz García, Clínica Pulmonar, Medellín, Colombia

Dr John E. Parker, Pulmonary and Critical Care Medicine, West Virginia University, Morgantown, West Virginia, United States

Dr Edward L. Petsonk, National Institute for Occupational Safety and Health (NIOSH), Morgantown, West Virginia, United States

Dr David J. Rees, National Institute for Occupational Health, Johannesburg, South Africa

Dr Prahlad Kumar Sishodiya, Labour Department, Building and Other Construction Workers' Welfare Board, Jaipur, India

Dr Ponglada Subhannachart, Central Chest Institute of Thailand, Nonthaburi, Thailand

Dr Narufumi Suganuma, Kochi Medical School, Kochi University, Kochi, Japan

Dr Chen Yu, National Institute of Occupational and Poison Control, China CDC, Beijing, China

**ILO Technical Secretariat**

Dr Begoña Casanueva Urcullu, ILO Headquarters, Geneva, Switzerland

Dr Francisco Santos-O'Connor, ILO Bangkok, Thailand

**Radiography readers who participated in the international image-reading trial of the new digitally acquired standards images and contributed to revising the *Guidelines* text:**

Dr Kazuhiro Suzuki, Juntendo University, Tokyo, Japan

Dr Robert Tallaksen, National Institute for Occupational Safety and Health (NIOSH), Morgantown, West Virginia, United States

## ▶ Guidelines for the use of the ILO International Classification of Radiographs of Pneumoconioses Revised edition 2022

In the continuing struggle to protect the health of workers occupationally exposed to airborne dusts, the ILO has for many years sought to improve the understanding of pneumoconioses. The 2022 revised edition of the *Guidelines for the use of the ILO International Classification of Radiographs of Pneumoconioses* is the latest version of a well-established publication designed to standardize classification methods and facilitate international comparisons of pneumoconioses statistics and research reports.

This revised edition of the *Guidelines* pertains to the ILO Classification of digital chest radiographs and replaces previous ILO standard digital images with a new set of digitally acquired standard digital images and further clarifies how the extent of pleural plaques are measured. It retains Chapter 6, which was added to the *Guidelines* in the 2011 revised revision and identifies principles for viewing digitally acquired images of the chest and covers effective acquisition, display, and storage of digital images.